

Restoration of the root canal treated tooth

S. Elias,^{*1} J. Jalili² and N. Martin³

VERIFIABLE CPD PAPER

IN BRIEF

- Provides a synopsis of the effects of root canal treatment on the strength of teeth.
- Summarises the available literature pertaining to the restoration of root filled teeth.
- Gives practitioners information on how to choose the appropriate temporary, interim and definitive restorations required for anterior and posterior root filled teeth.

PRACTICE

When considering endodontically treated teeth, the quality of the restoration is important from the outset. It sheds light into possible causes of pulp necrosis or failure of endodontic treatment and influences the outcome of future endodontic treatment. A tooth undergoing endodontic treatment requires an effective coronal seal during and following completion of endodontic treatment. This paper discusses, using the available literature, the maintenance of optimal coronal seal and coronal integrity during and after root canal treatment.

INTRODUCTION

Root canal treatment involves the removal of necrotic and infected tissue followed by the provision of a well-condensed obturation to prevent further microbial proliferation within the canal system.¹ The potential ingress of microbes into the canal system will compromise the outcome of endodontic treatment. The importance of an effective coronal seal in endodontics is well documented (Table 1).

A root filled tooth is unlike a vital tooth due to the effect of endodontic treatment. It is thought that endodontic treatment leads to 'weakening' of the remaining tooth structure as a result of various factors: changes in tooth architecture, changes in the properties of dentine and changes in proprioception. Although the effects are similar for both anterior and posterior teeth, the consequences are different due to the difference in tooth morphology and loading patterns.

The changes in tooth architecture are often attributed to the access cavity preparation and removal of the vital tissues, supposedly rendering the tooth weaker and more

Table 1 The importance of a good coronal seal (GE = good endodontics, GR = good restoration)

Study	Measure of coronal seal	No. of teeth	Outcome
Ray & Trope ⁹⁰	Rads	1,010 (no post + cores)	GR more important than GE
Tronstad <i>et al.</i> ⁹¹	Rads	1,000 (post + cores included)	GE more important than GR
Kirkevang <i>et al.</i> ⁹²	Rads	773	Better periapical status with GR
Hommez <i>et al.</i> ⁶²	Exam & rads	745	Better periapical status with GR
Boucher <i>et al.</i> ⁶³	Rads	5,373	No coronal restoration more periapical areas
Segura-Egea <i>et al.</i> ⁹³	Rads	93	Better periapical status with GR
Tavares <i>et al.</i> ⁹⁴	Rads	1,035	Better periapical status with GR
Ng <i>et al.</i> ¹¹	Exam & rads	1,452	Better periapical status with GR

susceptible to fracture. In anterior teeth, no difference in fracture susceptibility of root-filled and non-root-filled anterior teeth has been shown.² In posterior teeth endodontic procedures were shown to reduce the stiffness of teeth by 5%, however, the presence of an occlusal restoration reduced stiffness by 20% and the presence of a mesio-occluso-distal restoration reduced tooth stiffness by 63%.³ It is the loss of the marginal ridges and occlusal isthmus that leads to weakening of teeth.^{3,4} Some have theorised that obtaining straight-line access may weaken adjacent cusps;⁵ others have suggested that post preparation removes radicular dentine, which weakens teeth⁶ or that excess force during canal obturation causes tooth weakening.⁷ However, it must be remembered that most teeth requiring endodontic treatment have already suffered caries, cracks, trauma and previous restorations which may be the cause of weakness.

Proprioception is also purportedly affected by endodontic treatment with higher pain threshold seen in non-vital teeth and therefore increased loading of non-vital teeth. It is thought that proprioception is reduced by 30% after endodontic treatment as a result of pulpal nerves being involved in regulating masticatory load.⁸ The periodontal ligament may act as a protective feature. The relevance of loading forces may be more prudent in parafunctional patients as parafunctional loads can be six times the normal chewing force (1.5 to 7 kg) for an excess of 35 minutes in 24 hours, whereas normally teeth come together for chewing and empty swallows (eight minutes) for about 17.5 minutes every 24 hours. Chewing forces are predominantly vertical, but in parafunction they can also be horizontal,⁹ though in anterior teeth there is a much greater horizontal vector of force depending on the guidance on the

¹Locum Consultant in Restorative Dentistry, Glenfield Hospital, University Hospitals of Leicester NHS Trust, Groby Road, Leicester, LE3 9QP; ²Specialist Registrar in Restorative Dentistry, Charles Clifford Dental Hospital, Sheffield Teaching Hospitals NHS Foundation Trust, Wellesley Road, Sheffield, S10 2SZ; ³Professor and Hon Consultant in Restorative Dentistry, Academic Unit of Restorative Dentistry, School of Clinical Dentistry, University of Sheffield

*Correspondence to: Miss Shiyana Elias
Email: shiyanaelias@hotmail.com

Refereed Paper

Accepted 12 November 2014

DOI: 10.1038/sj.bdj.2015.27

©British Dental Journal 2015; 218: 53–62

anterior teeth. However, nothing is reported in the literature in relation to parafunction and failure of endodontically treated teeth.

The process of endodontic treatment predominantly results in collagen depletion; this affects the elasticity of the dentine and predisposes to fracture during shearing forces. A number of steps in the protocol of root-canal treatment have a negative effect on collagen including the use of sodium hypochlorite (NaOCl), with concentrations over 2% having more deleterious effects.¹⁰ There is a synergistic effect of ethylenediaminetetraacetic acid (EDTA) and NaOCl.¹⁰ The use of calcium hydroxide (Ca(OH)₂) dressing can reduce the flexural strength of dentine and microbial products themselves can degrade collagen.¹⁰ Heat created during treatment can further denature collagen and dehydrate the tooth structure, although the loss of pulp or loss of moisture *per se* has not been shown to affect biomechanical properties of dentine.¹⁰ NaOCl, EDTA and Ca(OH)₂ are essential for the successful outcome of root-canal treatment¹¹ yet affect the strength and restorative viability of the remaining dentine.

It is noteworthy that although all root filled teeth are somewhat ‘weakened’ often as a result of injury before endodontic treatment, the anterior and posterior teeth are loaded differently in function and therefore interim and definitive restorations on root filled teeth should provide favourable load distribution as to prevent potential fracture of the remaining tooth structure. The same type of restoration is not ideal for both anterior and posterior teeth. The restorative component of endodontic treatment should optimise the tooth’s survival with a good coronal seal, cuspal protection where required and prevention of further primary disease. This article outlines the available evidence for the restoration of root filled treated teeth, both during and after endodontic treatment.

A ‘GOOD CORONAL SEAL’

The development of apical areas occurs only in the presence of microbial invasion of the canal spaces.¹²⁻¹⁴ Laboratory studies have shown that bacteria can reach the apex of root filled teeth in as short a period of time as a few days, and the endotoxins can reach the apex even faster.¹⁵⁻¹⁷ Endodontic treatments are often carried out on teeth that have had their coronal seal compromised. Consequently when a tooth is requiring endodontic treatment an assessment of the existing coronal seal is imperative.

In teeth that show pulpal problems soon after crown and bridgework, the loss of vitality may have resulted from the preparation carried out (Table 2), however, where the

Table 2 The incidence of pulp death under crown and bridgework

Study	Number of teeth	Method of assessment	Follow up	Pulp death (crowns)	Pulp death (bridges)
Bergenholtz & Nyman ⁹⁵	417 crowns 255 bridge abutments	Notes & rads	4-13 years	3%	15%
Karlsson ⁹⁶	944 bridge abutments	Exam & rads	10 years	-	10%
Jackson <i>et al.</i> ⁹⁷	202 crowns 235 bridge abutments	Exam & rads	2-6 years	5.7%	
Valderhaug <i>et al.</i> ⁹⁸	46 crowns 112 bridges	Rads	25 years	17%	
Saunders & Saunders ⁹⁹	458 crowns	Rads	?	19%	-
Cheung <i>et al.</i> ¹⁰⁰	284 crowns 102 bridges	Exam & rads	7-21 years	16%	33%

Table 3 Detecting the quality of the coronal seal before and after dismantling restorations (Abbott 2004)²²

	Before restoration removal	After restoration removal
Caries	47 (19.2%)	211 (86.1%)
Cracks	57 (23.3%)	147 (60%)
Marginal breakdown	96 (39.2%)	244 (99.6%)

crown has been present for any length of time, the loss of vitality or failure of endodontic treatment may be as a result of leakage which is likely to go undetected if the coronal restoration is not dismantled. In few exceptional situations, there may be a need to maintain the restoration and access the canal system through the existing restoration, such as the need for endodontic treatment following very recent provision of a cuspal coverage restoration.

The retention of the restoration will be affected by the act of making an access cavity within the restoration. In anterior teeth there may be up to a 60% decrease in the retention of crowns following endodontic access through the existing crown.¹⁸ Based on the effect of ultrasonic energy on post removal, the use of ultrasonic energy as part of the endodontic access procedure may further affect the cement lute of the crown.^{19,20} The patient must be informed that the restoration may decement during or after the procedure rendering the need for a new crown to be constructed. In posterior teeth the decrease in retention is related to the area of the access cavity as a proportion of the total area of the preparation.²¹

It has been shown that the clinical and radiographic assessment of a coronal restoration while *in situ* is not always accurate. Abbott (2004) assessed 245 teeth before and after removal of the coronal restoration and showed that there was a 56% chance of detecting caries, cracks or marginal

breakdown from clinical and radiographic examinations (Table 3).²² This highlights the importance of coronal disassembly to determine the suitability for treatment and prognosis before endodontic treatment, especially with crowns and conventional cements. It is the authors’ experience that the true status of the cement interface can only be visualised once the restoration is sectioned and removed, thus enabling an accurate assessment to be made.

Although maintaining the restoration may be seen as advantageous for retaining rubber dam clamps, the presence of crowns and large amalgam restorations can hinder visibility significantly. Where crowns are present, there may also be loss of orientation leading to the potential for iatrogenic errors in locating canals and removal of significantly more dentine than necessary, compromising the restorability and the prognosis.^{11,23-26} The presence of a metal restoration can hamper the use of electronic apex locators, which is integral to identifying the apical constriction in many cases.^{27,28} Where the apex is large due to trauma during root development, resorption or where periendo lesions exist, a second additional form of identifying the apical constriction is necessary, such as using paper points.^{29,30}

The reluctance to remove posts as part of coronal disassembly is often due to the potential risk of root fracture; however, Abbott (2002) showed that posts could be removed without risk of fracturing the root.

He removed posts from 1,600 teeth, and only 0.06% suffered a fracture of the root (one tooth which was thought to have a fracture present before post removal).³¹ The average time taken to remove a post was three minutes using the Egglar post removal device and ultrasonic activation.³¹ The key is to ensure careful sectioning and removal of the overlying crown. The core material must then be removed around the post to leave part of post above gingival level for many of the available post removal devices to be used with ease. Ultrasonic activation is crucial to post removal, although when ultrasonic instrumentation is used dry, repeated wetting and cooling of the tooth is necessary to prevent overheating of the periodontal tissues. It is essential to ensure the water reaches the working tip of the ultrasonic instrument. Monitoring of the post temperature at one to two minute intervals (less if the remaining dentine around the post is thin), along with two-minute rest periods when ultrasonics are being used for more than ten minutes to allow recovery of the tissues has been suggested.³² It is recommended that an immediate denture is kept ready prior to dismantling coronal restorations on heavily restored anterior teeth.

Once restorations are disassembled, assessing the restorability of the tooth in health economic terms is essential. Wasting resources on an unrestorable tooth that is likely to fail due to the poor coronal seal is unwise and the resources may be better spent extracting the tooth and considering the options for replacement. Evidence based dentistry involved decision-making using the best available evidence, clinical judgement and patient choice. The decision to dismantle and endodontically treat a tooth is difficult when a patient presents without symptoms and the tooth is heavily restored or restored with an extra-coronal restoration. The tooth may or may not be restorable and it may be difficult to assess without dismantling the restoration. If the tooth is found to be restorable, taking the risk and completing the endodontic treatment as soon as possible is advantageous as the longer the tooth is left infected the more resistant the microbial colonies may become.^{33,34} If however the tooth is unrestorable after dismantling, the patient may see it as a premature loss of tooth if s/he presented without debilitating symptoms.

The restorability of a tooth is dependent on both the height and thickness of the available dentine following not only the removal of all restorations but also following preparation for any extra-coronal restorations.³⁵ If a tooth lacks a minimum of 2 mm of height and 1 mm of width of

dentine supragingivally following coronal disassembly and crown preparation, the tooth is deemed unrestorable without crown lengthening procedures as this is important to achieve an adequate ferrule effect. The aesthetic consequences, length of the root and periodontal support usually determine the possibility of crown lengthening procedures. The width of the remaining dentine once crown preparation is completed must be visualised: in vital teeth, thin remaining dentine may endanger the pulp whereas in root filled teeth thin remaining dentine will lead to coronal fracture.

Dismantling restorations implies the need for replacement restoration during and following endodontic treatment. Although numerous studies have highlighted the importance of a 'good coronal seal' in root filled teeth, what determines a 'good coronal seal' in real life clinical dentistry is less well documented. The ideal restorative material provides all of the structural properties to withstand failure under loading in the oral environment but also provides protection from the ingress of substances from the oral cavity into the tooth.

Assessment of marginal integrity and resistance to leakage is determined by *in vitro* studies due to the inability to assess leakage in a clinical scenario without removing the restoration. These include dye penetration, bacterial penetration or radioactive isotope penetration. Despite the sophistication of some of these, the biological differences of the oral environment cannot be ignored with the result that these studies cannot be extrapolated directly to clinical practice. If the bacterial endotoxins can penetrate restorations and cause apical periodontitis, leakage studies relating to bacterial penetration alone are not useful. An ideal material providing an ideal seal is not documented in the literature at present.

The restoration of a root filled tooth begins before root filling with interim restorations, during root filling with temporary restorations and after root filling with definitive restorations.

INTERIM RESTORATIONS

Interim restorations are those that provide structural integrity to the tooth while the tooth is undergoing endodontic treatment. This restoration is provided following dismantling and assessment of the tooth restorability, usually before or in the early stages of endodontic treatment. An interim restoration is expected to remain *in situ* providing a good seal until the endodontic treatment is completed and a definitive restoration can be provided. These interim restorations should help provide support for weakened cusps

preventing fracture between appointments as well as a good coronal seal. Interim restorations can also aid rubber dam isolation during endodontic treatment, which is both important to prevent ingress of microbes into the canal system but is also vital in ensuring hazardous canal irrigants do not seep into the oral cavity during treatment.

Where there is a small existing intracoronal restoration, the temporary restoration may act also as the interim restoration. Where the tooth's coronal structure is severely compromised or a crack is suspected, copper rings or orthodontic bands may act as interim restorations (Figs 1 and 2). Some have advocated the use of stainless steel orthodontic bands as interim restorations citing reduced cusp flexure often in premolar teeth³⁶ and recommended that if one or more cusps are missing a band should be placed.³⁷ When metal bands are used, it is prudent to use chemically curing cements as well as ensure that the margins allow optimum oral hygiene and that the restoration is in keeping with the occlusion. It is not always possible to use metal bands around teeth in smile line such as premolars due to

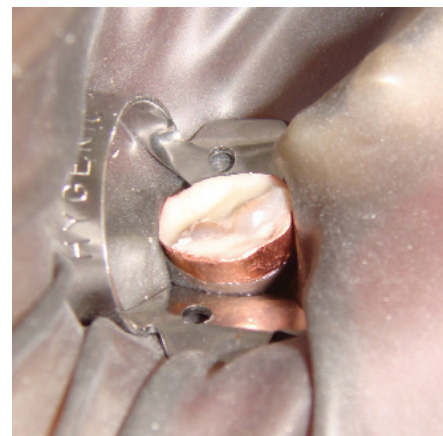

Fig. 1 Interim restorations using copper rings

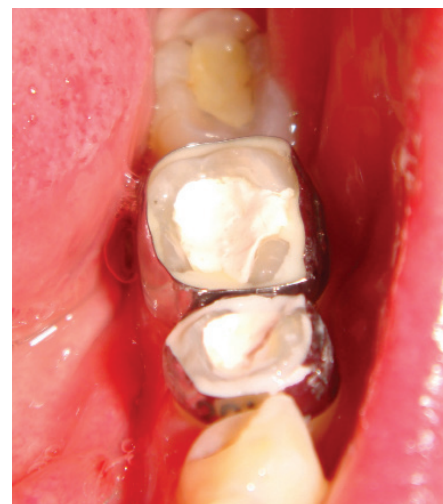

Fig. 2 Interim restorations using orthodontic bands

aesthetic considerations, although using a tooth coloured material to mask the buccal surface of the metal band have been described.³⁷ Entire tooth build-ups using glass ionomer cements, composite materials and amalgam have been described in detail in endodontic textbooks.³⁸

When anterior teeth are undergoing endodontic treatment, if the tooth is unrestored or restored with intracoronal restorations, a temporary restoration in the endodontic access cavity may be the only requirement. In cases where a crown is dismantled, the authors recommend a temporary restoration be placed in the endodontic access cavity before placement of the temporary crown, so that if the crown is lost, the access cavity still remains sealed. These temporary crowns can be easily constructed using a putty index of the tooth before coronal disassembly and a chair side temporary crown composite material such as Prottemp (3M ESPE, Seefeld, Germany) or Quicktemp Cosmetic (Davis Schottlander & Davis Ltd. Fifth Avenue, Herts, UK) or cold cure acrylic material such as Trim (The Bosworth Company, Skokie, IL) or Snap (Parkell, Inc. NY, USA). The choice is often dependent on personal preference. The marginal integrity is important for the seal and the marginal contour is essential for the health of the periodontal tissues. It has been recommended that temporary crowns be cemented with Intermediate Restorative Material (IRM® - Dentsply Caulk, DE, USA) or zinc phosphate cement.³⁷ It may also be appropriate to consider a sealing the dentine tubules with a dentine-bonding agent following crown preparation to reduce the risk of bacterial leakage via the exposed dentine tubules.³⁹

It is more difficult to obtain a good coronal seal with temporary post crowns. Some have stated that teeth restored with temporary posts have as much contamination as not having a restoration *in situ*.^{40,41} It is recommended that cotton wool and Cavit (3M ESPE, Seefeld, Germany) be placed at the base of the post cavity before cementation of the post and crown,³⁷ though their removal can pose difficulties. As a result it may be more appropriate to avoid a post crown and use an immediate or temporary denture (RPD) for anterior teeth, with the root stump sealed and protected using a temporisation material until the endodontic treatment is completed.⁴² Clearly, if a temporary acrylic RPD-overdenture is to be used, this needs to be planned and discussed with the patient from the outset. Instructions to the technician should make it clear that an overdenture is required and that this is not conventional in the amount of tooth reduction. Clear guidelines should be provided to

the technician with the approximate amount of tooth that will be left *in situ* under the denture tooth. The acrylic denture will doubtless need significant adjustment over the remaining coronal tooth structure of the tooth undergoing root canal treatment – this should be done by hollowing out the denture in this area and relining at chairside over the tooth in question.

In posterior teeth, if there is adequate tooth structure, a temporary material in the endodontic access cavity alone may be sufficient. However, if a crack is suspected, providing cuspal coverage may be required. This can be in the form of the entire tooth being built up with a restorative material as discussed earlier, or the provision of a temporary crown in a similar manner to an anterior tooth.

In some cases it may be necessary to reduce the occlusal surface of the tooth and rebuild using a restorative material such as amalgam to provide better force distribution to prevent the occurrence of a vertical fracture.^{43,44} Although amalgam provides adequate strength in these situations, the metallic nature can interfere with apex locators and the dark colouring can hinder visual inspection of the canal system. Other materials such as composite are an alternative although their use can be time consuming and their removal may remove further tooth structure. Due to the need for good moisture control when using composite and glass ionomer cement (GIC), in badly broken down teeth the more forgiving amalgam restoration may be a better alternative. The endodontic access cavity of ideal dimensions can then be made through this restoration, with care not to jeopardise the integrity and stability of the interim restoration.

TEMPORARY RESTORATIONS

Temporary restorations are those that occupy the access cavity and provide a good coronal seal between appointments. The overriding requirement is that they should provide an effective and durable seal between appointments. Other desirable properties include ease of removal at the next appointment, inexpensive and having inferior aesthetic properties, thus making it more obvious at the time of removal so that additional tooth structure is not removed at the subsequent re-entry appointment. An array of potential materials are available, including zinc-oxide/calcium-sulphate-based materials (Cavit, Coltosol – Coltene Whalident, Mahwah, NJ, USA), zinc-oxide-based reinforced intermediate restorative materials (IRM – Dentsply Caulk, Milford, USA), GIC, resin modified GIC (RMGIC), reinforced GIC (Ketac Fil and Ketac Silver – 3M ESPE, Seefeld, Germany), composite (TERM – Dentsply Maillefer,

Switzerland), amalgam and temporary crowns ± posts. It is possible to use the same materials in endodontic access cavities of both anterior and posterior teeth.

Temporary materials must have adequate strength but often do not require that essential for interim restorations, although this does depend on the loading pattern of the tooth. Temporary materials are used in smaller quantities and must maintain its strength in small quantities. In terms of the sealing ability of available temporary sealing, somewhat contradictory evidence exists.³⁷ The sealing ability may be affected by the deformation of the material under cyclic loading⁴⁵ and the ability of the material to withstand marginal breakdown and/or leakage.

A summary of the literature relating to endodontic temporisation by Naoum and Chandler (2002) discusses a variety of temporary materials tested for use in endodontic access cavities.⁴⁶ They found that gutta percha (GP) produced a poor seal and there was contradictory evidence with regard to the sealing ability of zinc phosphate cements and polycarboxylate cements. Zinc oxide/calcium sulphate preparations such as Cavit showed good marginal sealing due to their water absorbing characteristics. However, a number of studies showed dye penetration into the body of the material. A 3.5–4 mm thickness of material was required for an adequate seal. Coltosol is a similar material to Cavit and is said to harden within 30 minutes on contact with moisture however has not been tested as an endodontic temporary material. IRM, a zinc-oxide-eugenol-based material, also had contradictory evidence with some studies showing ability to prevent bacterial penetration into tooth cavities others showing high fluid penetration along the margins depending on the consistency of the mix. The softer, sticky mixes gave better antimicrobial activity and better seals but with reduced physical properties. A powder to liquid ratio of 6:1 was recommended for better strength.

GIC was said to give a good a seal as an intact crown over eight weeks, with its antibacterial properties and chemical bond to tooth structure. Reinforced GICs have higher flexural strengths.⁴⁶ Other *in vitro* studies have shown that GIC can give a better seal over other materials.^{47–50} There is the added disadvantage of removing more tooth structure when these interim materials are removed. Conditioning with polyacrylic acid before placement of GIC was recommended for a more predictable bond followed by varnish or resin seal over the GIC to protect from water absorption.^{51,52}

When composite materials were

considered, the shrinkage and material thickness (minimum of 2 mm) was important in determining sealing ability. Some studies showed that the seal with composite was inferior to Cavit and IRM. This may be as a result of attempting bonding to tooth structure damaged by endodontic medicaments as it has been shown that bonding of resin to tooth structure is reduced after endodontics.^{53,54} *In vitro* studies showed that Cavit, TERM, GIC and IRM all gave leak proof seals when placed in access cavities made through amalgam interim restorations. Cavit and zinc-oxide-eugenol-based materials gave a good seal if the access was through a composite interim restoration. Cavit and IRM provided as good a seal as the original restoration when placed in access cavities through interim IRM restorations, amalgam fillings and gold or metal ceramic crowns.⁴⁶

The concept of a 'double seal' has also been described in the absence of a single ideal restorative material. A double seal is the placement of two temporary materials in the access cavity to gain the advantages of both materials such as the sealing ability of one material and the strength of another.

The combination of Cavit and IRM have been recommended for various reasons including cost, ease of use and the fact that used together better dentine adaptation was seen when compared with IRM alone.⁵⁵ GIC could also be used as stated earlier as it shows good sealing ability. Where internal bleaching or in-out bleaching are considered, due to the expansion of bleaching agents, Cavit or Coltosol placed in sufficient thickness over the GP are recommended instead of composite as a temporary restoration. GIC, composite or amalgam can be used over a layer of temporary material such as Cavit, if longer-term temporisation is required.⁴⁶

Cotton wool underneath temporary materials is discouraged due to the requirement

of space for the temporary restoration, leakage through exposed dentinal tubules, acting as a cushion for the temporary filling to be displaced and potential for microscopic cotton fibres to be either exposed to the mouth and thus wicking saliva and bacteria into the pulp chamber or being carried down the canal in to apical tissues. Alternatively a sterile, well-adapted piece of polytetrafluoroethylene (PTFE) tape⁵⁶ or in the authors' experience, sponges such as Roeko Endofrost Pellets (Coltene Whalident, Mahwah, NJ, USA) can be used over the canal orifices as they can be compressed under the packing force of the temporary material and removed easily without fibres being carried apically. It is advised that the cavity is dried before temporary material placement and that the material is condensed in increments.⁴⁶

DEFINITIVE RESTORATIONS

The definitive restoration should be placed as soon as possible after completion of root canal treatment. The time it takes for the microbial penetration of the canal if the temporary restoration is lost has been shown to be as low as two days in animal studies.⁵⁷

It is clear that a definitive restoration is essential as Chugal (2007) found that 40% of teeth with temporary restorations failed when compared with 21% failure of those with definitive restorations.⁵⁸ There may be some selection bias here as teeth with pre-apical periodontitis may be more likely not to be restored with crowns as endodontic failure is expected. Chugal found no difference in endodontic failure rates between crowns, amalgams or composites.⁵⁸ Endodontically treated premolars restored with fibre posts and direct composite have been compared to the restoration of premolars using amalgam. No statistically significant difference was found between the proportions of failed teeth in the two groups, however, more root

fractures and less caries was observed in the teeth restored with amalgam at five years.⁵⁹ A Cochrane review included one study with high risk of bias⁶⁰ where premolars were root filled, carbon fibre post placed and then restored with either a composite material or built up with composite followed by a full coverage metal ceramic crown. They concluded that there were no differences between the non-catastrophic failures in both groups and that insufficient evidence exists to refute the use of conventional fillings over crowns for the restoration of root filled teeth.⁶¹

The need for a post is debatable as Hommez *et al.* (2002) found that posts and marginal caries had no influence on apical status.⁵² Apical periodontitis in this study was increased if there were 'unacceptable' restorations *in situ* (49% vs. 24% for acceptable restoration), if there was no base under restorations (41% vs. 26% if a base was present), or if composite was used (41% vs. 28% if amalgam was used). Boucher *et al.* (2002) showed apical periodontitis in 29% of cases with posts, 22% with intracoronar restorations, 24% with extracoronar restoration and 33% with no coronal restoration.⁶³

Ferrari *et al.* (2012) studies 354 premolars with posts and metal ceramic crowns receiving a variety of treatments including no post, prefabricated composite post and customised fibre posts. The overall survival of teeth was 94% at six years. If there was no post present the survival was 86%, with a prefabricated post survival was 99% and with a custom post the survival was 97%. The teeth in the study were divided according to the number of walls remaining (six groups of 60 teeth each). Teeth with four walls did not fail regardless of the type of post. However, the study implied that catastrophic failure was highest if there was no post and a crown was provided where there was one, two or three walls remaining, regardless of a presence of a ferrule.⁶⁴ A Cochrane review found poor quality evidence in support for which post is best.⁶⁵ Table 4 summarises the evidence for survival of different post types. From the view of maintaining a good coronal seal, the direct placement of a post and core at the time of completion of the root canal treatment is ideal, followed by the provision of a temporary crown.

Prior to placement of a definitive restoration, a canal orifice seal is recommended. This is 3-4 mm of a well sealing material such as IRM or Cavit or GIC. Some suggest that eugenol-based materials are helpful as eugenol does well against bacterial leakage. Others have noted that eugenol can affect the bonding properties of resins. This evidence is conflicting with some proposing that etching

Table 4 Outcome of posts

Study	Type of post	Survival
Weine ¹⁰¹	Cast post and cores	99% at 10 years
Mentink ¹⁰²	Cast post and cores	82% at 10 years
Creuger (meta analysis) ¹⁰³	Screw post and composite Cast post and cores	75-87% at 6 years 88-94% at 6 years
Jung ¹⁰⁴	Titanium posts and composite build ups Case post and cores	93.5% at 8.5 years 90.2% at 8.5 years
Signore ¹⁰⁵	Glass fibre posts and all ceramic crowns	98% at 8 years (root fracture)
Tidehag ¹⁰⁶	Carbon fibre posts	90% at 7 years
Segerstrom ¹⁰⁷	Carbon fibre posts	65% at 6.7 years
Nauman ¹⁰⁸	Glass fibre posts	87% over 2 years (post fracture)

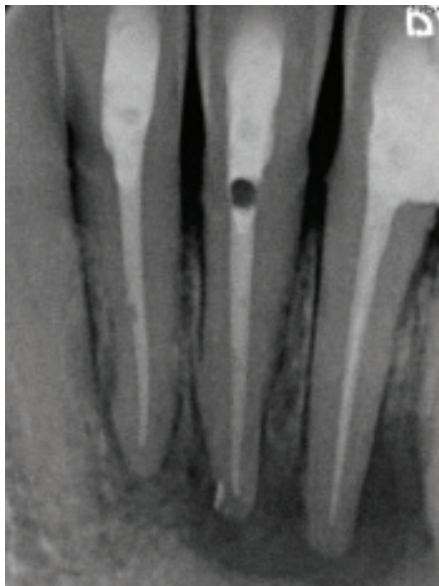
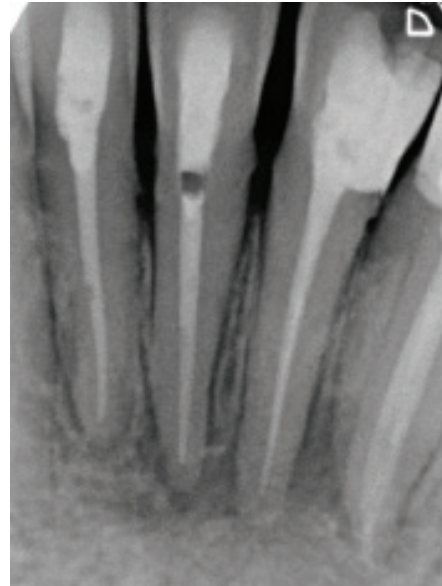

Fig. 3 Trapping of air in narrow access cavities when restoring with resin composites (a: immediately post operatively, b: one-year review)

with 30-35% phosphoric acid for 15 seconds removes eugenol in the dentinal tubules to a sufficient depth (ten microns). Therefore it may be more appropriate to use RMGIC when composite is to be used as the main restoration. The bond strength of GIC is unaffected by IRM or Cavit.⁶⁶ Residual endodontic sealers can also adversely affect bonding and a total etch procedure is recommended.⁴⁶ GIC must be sticky to form a bond with tooth structure, yet also be packed down into the canal orifices. Composite can also be used, although air blows easily occur and adequate drying and curing to the depth of the canal orifice may be difficult to achieve (Fig. 3).

In most anterior and premolar teeth, the pulp chamber is small and the placement of a post may aid the retention of the definitive restoration, even when the tooth is not to be crowned. In posterior teeth the pulp chamber is sufficiently large to retain core materials and should be used to do so without the need for a post. A guide to choosing the correct post has been published elsewhere.⁶⁷ When a post is required, from an endodontic perspective, the ideal is to seal the canal immediately with a direct post and core, however in oval or irregular canals, when a cast post is required this may not be possible. Pink GIC (Fuji VII Command Set (GC Asia Dental, Singapore) can be very useful for sealing over GP when a temporary post and crown is to be placed after root filling. Pink GIC is chemically cured (accelerated with Halogen light) and has the added advantage of a mismatch in colour, which allows for safer removal if endodontic re-treatment is required in the future.

The type of definitive restoration to be provided depends on the amount of tooth structure remaining and the amount and direction



of loading. Anterior teeth are loaded non-axially. Posterior teeth are loaded occlusally and therefore axially. The options for anterior teeth are direct composite restorations or replacement crowns with or without a post. The options for premolars is similar although these teeth are often loaded axially and may be loaded horizontally if they are involved in lateral guidance and cuspal coverage should be considered where marginal ridges are compromised (Fig. 4). Molars can be restored with simple composite or amalgam restorations in the access cavity if the marginal ridges are intact or complex amalgams/composite providing cuspal coverage, onlays/overlays in gold (Fig. 5), indirect composite or porcelain, or full coverage crowns in metal, metal ceramic or all ceramic if marginal ridges are compromised.

When crowns are considered, the need for a ferrule is mandatory for a more predictable restoration. A ferrule is a band of the crown material (often metal) that completely encircles the external dimensions of the tooth and lies between the most cervical dentine-core interface and the cervical crown margin. This is strongly recommended where posts are placed as it resists lateral forces and thus providing fracture resistance.⁶⁸ Ferrules must be on sound tooth structure (not the core) and axial walls must be parallel and minimum thickness of 1 mm.³⁸ The longer the ferrule the better with minimum of 1 mm height suggested by some.⁶⁹ Ferrules should not invade periodontal attachment and therefore must be more than 0.4 mm from the base of the gingival crevice, although the depth of the gingival crevice may vary from patient to patient with the average biological width being approximately 2 mm.⁷⁰

Traditionally the height of preparation

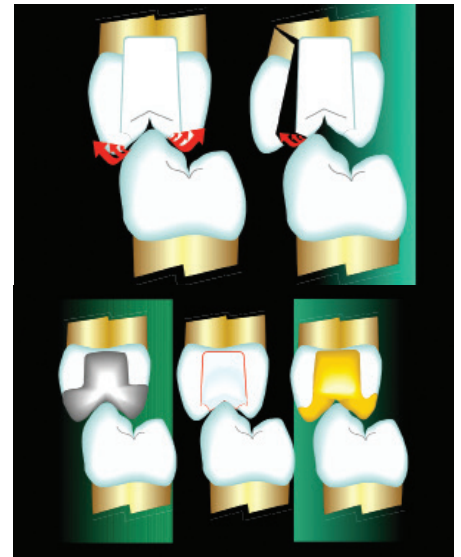

Fig. 4 Forces leading to fracture of cusps where cuspal coverage is not used and the marginal ridges are compromised

required for retention and resistance form is dependent on the taper of the preparation. It has been said that although 2-6° tapers are ideal, clinicians realistically achieve 10-20° tapers. In the anterior zone a minimum of 3 mm of height and in the posterior zone where it is more difficult to achieve the ideal taper, 4 mm of height is required.⁷⁰ This may be less of an issue where adhesive cements are used. Posts can also be advantageous to retain core materials, which can in turn help retention and resistance form. New composite materials predictably bond to dentine, although the long term bonding is affected by shrinkage, hydrolysis, cyclic loading and thermal stresses in function.⁷¹ This may be a limited problem where the entire restoration is covered by a crown. As said earlier, the bonding to endodontically treated teeth may also be unpredictable.

Nayyar cores (Fig. 6) are useful in posterior teeth as amalgam can be packed 2-3 mm into the canal orifice avoiding the need for a post and providing an orifice seal. It is also possible to place 3 mm of IRM or Cavit in the canal before the placement of an amalgam restoration. Bonded amalgam restorations have been shown to have strength almost comparative to unrestored teeth, and strengths higher than bonded composite restorations although no statistical significance was found between the two groups.^{72,73} Composite used for cuspal coverage in endodontically treated premolars has been shown to give fracture resistance similar to untreated teeth and higher fracture resistance compared to intracoronary composite restorations.⁷⁴ Both amalgam and some GICs must set for 24 hours before crown preparation. Some modern GICs (for example, Chemfil Rock, Dentsply Caulk,

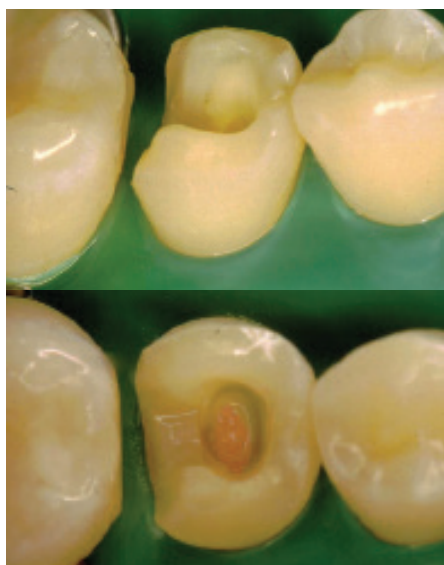


Fig. 5 The use of an inlay/onlay for cuspal coverage

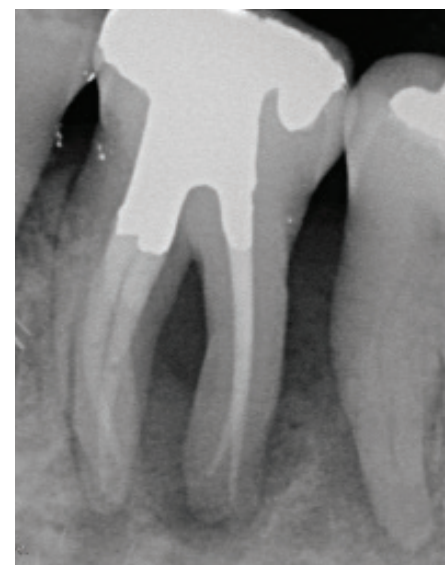
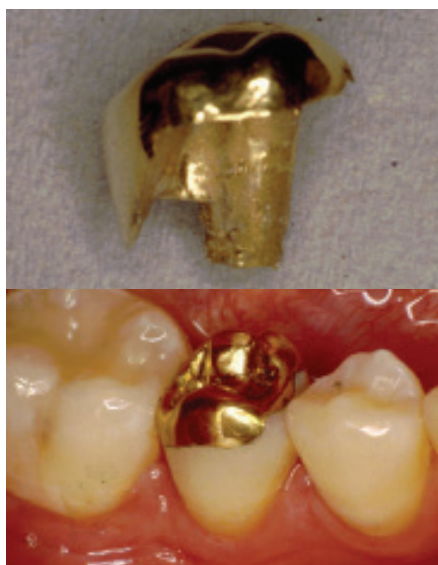

Fig. 6 Example of a Nayyar core restoration on the 36

DE19963) do not require 24 hour setting and the manufacturers advocate finishing immediately post set (within a few minutes). Glass-ionomer-cement-based core materials are often avoided as GICs expand with moisture contamination.

In a mutually protected occlusion, anterior teeth experience occlusal forces with lateral vectors during function to protect posterior teeth in guidance. The cervical band of tooth structure especially on the palatal aspect is very important in distributing lateral loads and crown preparations on anterior teeth can reduce the thickness of this band. This results in a reduction in the capability of the cervical portion of the tooth to withstand lateral forces thereby making the tooth prone to fracture of the coronal portion at gingival level. In Class II div 2 cases this is more important and if crowned, a stronger material is needed around the cervical collar than in an edge-to-edge occlusion. For the above reason, crowns on anterior teeth are best avoided (Fig. 7). In anterior teeth posts can be useful if a crown is to be placed, as the post will allow lateral load to be distributed away from the cervical area, however the load may then be at the apex of the post and root fracture may be a problem.

For posterior teeth, the ideal definitive restoration is dependent on the remaining tooth structure. Intracoronal restorations are only recommended if both marginal ridges are present. Where there is reluctance to provide a crown, a cuspal coverage amalgam restoration may be of use, although the following findings are not limited to endodontically treated teeth. Smales and Hawthorn (1997) showed that 15-year survival for complex amalgams was 48% in comparison to 89% for crowns.⁷⁵ Plasman (1998) found that their survival of complex

amalgams at eight years was 88%.⁷⁶ Martin and Bader (1997) looked at survival of 4-5 surface amalgams *versus* crowns and found that crowns had higher success and lower catastrophic failure.⁷⁷ More recent studies on root filled teeth have also shown direct restorations to have lower ten-year survival rates than crowns (81% for crowns *vs.* 63% for amalgam, composite, cements).⁷⁸ The need for cuspal coverage is difficult to ascertain from the literature, although some have stated that access cavity preparation can result in greater cuspal flexure.⁷⁹ Biologically better force distribution in posterior teeth may be beneficial when taking into account the potential weakening caused by existing restorations and by loss of marginal ridges.

The relationship between crown placement and the survival of endodontically treated teeth is well documented. Aquilino and Caplan (2002) looked at 203 teeth; 129 were crowned following endodontic treatment and 74 were restored with amalgam/composite restorations.⁸⁰ Forty-two teeth (20.7%) were extracted: 14 with crowns and 28 teeth with direct restorations *in situ*. It was not clear how teeth were chosen for crowns and for amalgam or composite restorations. Not enough information was given about the size of the direct restorations and whether or not the direct restorations provided cuspal coverage. Although the reason for extraction was not mentioned, it was concluded that endodontically treated teeth were six times more likely to be lost if a crown was not provided and the outcomes were better if two proximal contacts existed. It was noted that teeth with caries at time of access had poorer 5-10 year survivals. Cheung and Chan in 2003 found that teeth restored with crowns survived significantly longer than those with intracoronal plastic restorations

alone, and teeth with an all-amalgam post and core or prefabricated post were associated with a significantly higher survival probability than when there was no post or when a cast post was used.⁸¹

An epidemiological study in USA looking at 1,462,936 endodontically treated teeth (21% anteriors, 27% premolars, 52% molars) using an insurance database showed that 41,973 teeth were extracted and 85% of those did not have full cuspal coverage.

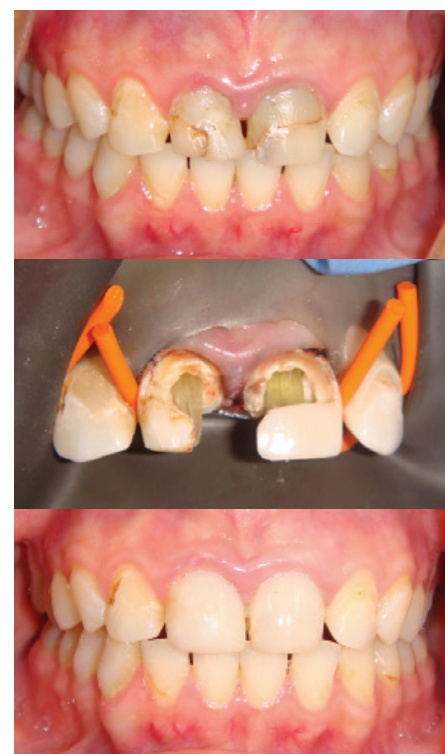

Fig. 7 Anterior teeth restored with composite (a: pre-operative view, b: interoperative view, c: post operative view). These teeth would not be suitable for crown placement due to the lack of remaining tooth structure following crown preparation

Teeth not provided with a crown were either not restored at all or restored with a multiple surface amalgam or composite. Where a crown was not provided, tooth extractions were 4.8 times higher in anteriors, 5.8 times higher in premolars and 6.2 times higher in molars compared to teeth with crowns. A statistically significant difference ($p < 0.001$) was found between teeth with a crown and those without.⁸² Tickle *et al.* (2008) reported on the failure rate of National Health Service funded molar endodontic treatment delivered in general dental practice in the UK. This retrospective cohort study of 174 teeth crudely measured the tooth survival for endodontically treated lower first molars. 38.5% of the teeth were crowned and none of these failed. Sixteen teeth failed in total. It was concluded that five failures per 100 root filled tooth years is expected, that is one in 20 root filled mandibular lower first molars restored with a plastic restoration will fail each year.⁸³

It must be remembered that endodontically treated teeth have an endodontic access cavity and any further preparation for an extra-coronal restoration may leave a very thin band of dentine, prone to fracture. Minimal preparation restorations are ideal to preserve tooth structure (Fig. 8). Gold onlays with a 1-2 mm chamfer margin on worn teeth have shown a survival of 89% at five years when 50 micron alumina abraded copper containing type III cast gold alloy was used and cemented with Panavia (Kuraray Noritake Dental Inc. Okayama, Japan).⁸⁴ Not enough

evidence exists yet for the use of these restorations in the outcome of endodontically treated teeth. Indirect composite resin onlays on root filled teeth have been shown to do well over 2-4 years with restoration survival of 96.8% and tooth survival of 100% over this time.⁸⁵

Glass ceramic onlays on endodontically treated teeth have demonstrated favourable outcomes with success rates of 92.5% over four years, however, this should be viewed with caution given the small sample size (53 endodontically treated molar teeth).⁸⁶ Shulte *et al.* (2005) reported the failure of nine out of a total of 246 ceramic onlays over 0-83 months.⁸⁷ Their results showed the survival probability of the ceramic restorations in root filled teeth exhibited no statistically significant difference to vital teeth with ceramic restorations, however a variety of clinicians performed the treatment on a variety of teeth in this retrospective analysis. Fracture resistance studies have shown that while gold onlays had improved fracture resistance when compared to glass ceramic and resin composite onlays, all onlay systems improve the fracture resistance when compared to unrestored teeth.⁸⁸ Indirect composite onlays have been shown to have good medium term survival (96% at 2-4years) in posterior teeth (31 premolars and 158 molars) *in vivo*.⁸⁵

Using endodontically treated teeth as abutments is discouraged where possible based on the work by Sorensen and Martinoff (1985) where the success of endodontically

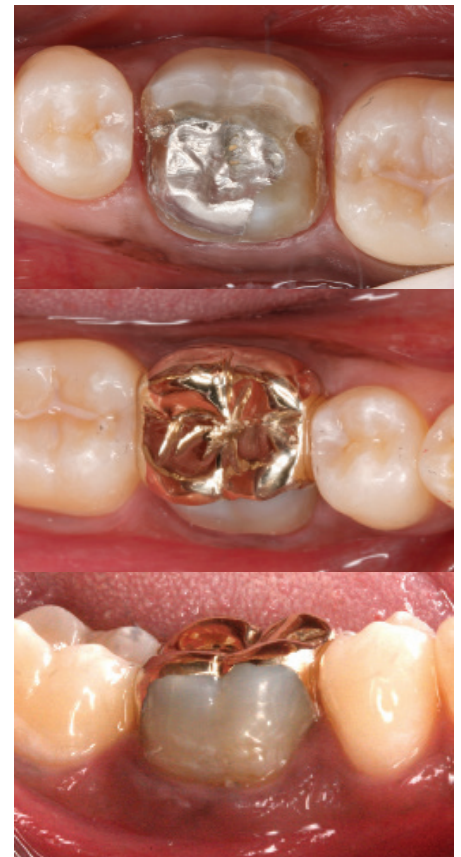

Fig. 8 The use of gold onlays preserves the remaining tooth structure while providing cuspal coverage

treated teeth restored with crowns was 95% in comparison to 89% for those used as abutments for fixed partial dentures and 77%

Table 5 Summary of restoration of the root filled tooth

Tooth type	No previous restorations (for premolars and molars where the marginal ridges are intact)			Previously heavily restored (for premolars and molars where one or more marginal ridges lost)			Previously crowned (for premolars and molars where both marginal ridges lost)		
	Interim	Temp	Definitive	Interim	Temp	Definitive	Interim	Temp	Definitive
Anteriors: Incisors Canines	Sponge, 3 mm of Cavit and 3 mm IRM or GIC or composite in access cavity		3 mm of GIC/RMGIC/Flowable composite orifice seal Conventional composite in access cavity	Tooth built up in GIC or composite prior to access cavity preparation	Sponge, 3 mm of Cavit and 3 mm IRM or GIC or composite in access cavity	Composite build up (or crown for canines)	Temp crown or leave as root stump with temp restoration & RPD overdenture for aesthetics (+/- temp post)	Sponge, 3 mm of Cavit and 3 mm IRM or GIC or composite in access cavity	Replace crown +/- post
Posteriors: Premolars Molars	Sponge, 3 mm of Cavit and 3 mm IRM or GIC or composite in access cavity		3 mm of GIC/RMGIC/Flowable composite orifice seal & conventional composite in access cavity OR Nayyar core amalgam restoration	Tooth built up in GIC or composite or amalgam prior to access cavity preparation Consider cuspal protection with plastic restoration or temporary crown/orthodontic band/copper ring	Sponge, 3 mm of Cavit and 3 mm IRM or GIC in access cavity	Consider cuspal protection with onlay or crown (gold onlay where possible)	Temp crown or leave as root stump with temp restoration (+/- temp post)	Sponge, 3 mm of Cavit and 3 mm IRM or GIC or composite in access cavity	Replace crown & amalgam Nayyar core where possible

for those used as abutments for removable partial dentures.⁸⁹

The authors' preferences for restoring root filled teeth are summarised in Table 5. The longevity of root filled teeth will not only depend on the quality of the root filling and the coronal restoration, but also the general oral health of the patient and primary disease control. It is prudent to ensure good oral hygiene, the prevention of caries with oral health education and the stability of periodontal disease with supportive periodontal treatment.

CONCLUSION

It is difficult to give absolute clarity when considering the ideal way to restore endodontically treated teeth. The evidence base is vague and each tooth will need individual assessment. Awareness of the biological needs, long term prognosis and understanding of the limitations of available materials goes a long way to providing the ideal restoration for endodontically treated teeth.

The authors acknowledge Dr Nicolas Jedynakiewicz for kind loan of the computer-generated graphic illustrations.

- European Society of Endodontology. Quality Guidelines for endodontic treatment: consensus report of the European Society of Endodontology. *Int Endod J* 2006; **39**: 921-930.
- Trabert K C, Caput A A, Abou-Rass M. Tooth fracture a comparison of endodontic and restorative treatments. *J Endod* 1978; **4**: 341-345.
- Reeh E S, Messer H H, Douglas W H. Reduction in tooth stiffness as a result of endodontic and restorative procedures. *J Endod* 1989; **15**: 512-516.
- Mondelli J, Steagall L, Ishikiriama A, de Lima Navarro M F, Soares F B. Fracture strength of human teeth with cavity preparations. *J Prosthet Dent* 1980; **43**: 419-422.
- Hansen E K, Asmusen E. Cusp fracture of endodontically treated posterior teeth restored with amalgam: Teeth restored in Denmark before 1975 versus after 1979. *ACTA Odontol Scand* 1993; **51**: 73-77.
- Trope M, Ray H L. Resistance to fracture of endodontically treated roots. *Oral Surg Oral Med Oral Pathol* 1992; **73**: 99-102.
- Pitts D C, Matheny H E, Nichols Y I. An *in vitro* study of spreader loads required to cause vertical root fracture during lateral condensation. *J Endod* 1983; **9**: 544-550.
- Randow K, Glantz P O. On cantilever loading of vital and non-vital teeth. An experimental clinical study. *Acta Odontol Scand* 1986; **44**: 271-247.
- Pameijer J H N. *Periodontal and occlusal factors in crown and bridge procedures*. PBC Amsterdam Dental Centre, 1985.
- Kishen A. Mechanisms and risk factors for fracture predilection in endodontically treated teeth. *Endodontic Topics* 2006; **13**: 57-83.
- Ng YL, Mann V, Gulabivala K. A prospective study of the factors affecting outcomes of non-surgical root canal treatment: part 1: periapical health. *Int Endod J* 2011; **44**: 583-609.
- Kakehashi S, Stanley H R, Fitzgerald R J. The effects of surgical exposures of dental pulps in germ-free and conventional laboratory rats. *Oral Surg Oral Med Oral Pathol* 1965; **20**: 340-349.
- Sundqvist G. *Bacteriological studies of necrotic dental pulps*. Umea University Odontological Dissertations, No 7. 1976.
- Möller A J. Microbiological examination of root canals and periapical tissues of human teeth. Methodological studies (thesis). *Odontol Tidskr* 1966; **74**: 1-380.
- Swanson K, Madison S. An evaluation of coronal microleakage in endodontically treated teeth. Part 1. Time periods. *J Endod* 1987; **13**: 56-59.
- Magura M E, Kafrawy A H, Brown C E, Newton C W. Human saliva coronal microleakage in obturated root canals: an *in vitro* study. *J Endod* 1991; **17**: 324-331.
- Alves J, Walton R, Drake D. Coronal leakage: endotoxin penetration from mixed bacterial communities through obturated, post-prepared root canals. *J Endod* 1998; **24**: 587-591.
- Yu Y C, Abbott P V. The effect of endodontic access cavity preparation and subsequent restorative procedures on incisor crown retention. *Aust Dent J* 1994; **39**: 247-251.
- Braga N M A, Alfredo E, Vansan L P, Fonseca T S, Ferraz J A B, Sousa-Neto M D. Efficacy of ultrasound in the removal of intraradicular posts using different techniques. *J Oral Sci* 2005; **47**: 117-121.
- Sharma A, Rahul G R, Poduval S T, Shetty K. Removal of failed crown and bridge. *J Clin Exp Dent* 2012; **4**: e167-172.
- Mulvey P G, Abbott P V. The effect of endodontic access cavity preparation and subsequent restorative procedures on molar crown retention. *Aust Dent J* 1996; **41**: 134-139.
- Abbott P V. Assessing restored teeth with pulp and periapical diseases for the presence of cracks, caries and marginal breakdown. *Aust Dent J* 2004; **49**: 33-39.
- Farzaneh M, Abitol A, Friedman S. Treatment outcome in endodontics: The Toronto Study. Phases I and II: Orthograde Re-Treatment. *J Endod* 2004; **30**: 627-633.
- De Chevigny C, Dao T T, Basrani B R *et al*. Treatment outcome in endodontics: The Toronto Study. Phases 3 and 4: Orthograde treatment. *J Endod* 2008; **34**: 131-137.
- Ng YL, Mann V, Gulabivala K. Tooth survival following non-surgical root canal treatment: a systematic review of the literature. *Int Endod J* 2010; **43**: 171-189.
- Ng YL, Mann V, Rahbaran S, Lewsey J, Gulabivala K. Outcome of primary root canal treatment: systematic review of the literature - part 2. Influence of clinical factors. *Int Endod J* 2008; **41**: 6-31.
- Real D G, Davidowicz H, Moura-Netto C *et al*. Accuracy of working length determination using 3 electronic apex locators and direct digital radiography. *Oral Surg Oral Med Oral Pathol Oral Radiol Endod* 2011; **111**: e44-e49.
- Silveira L F M, Petry F V, Martos J, Neto J B C. *In vivo* comparison of the accuracy of two electronic apex locators. *Aust Endod J* 2011; **37**: 70-72.
- Gordon M P J, Chandler N P. Electronic apex locators. *Int Endod J* 2004; **37**: 425-437.
- Kim Y J, Chandler N P. Determination of working length for teeth with wide or immature apices: a review. *Int Endod J* 2013; **46**: 483-491.
- Abbott P V. Incidence of root fractures and methods used for post removal. *Int Endod J* 2002; **35**: 63-67.
- Gluskin A H, Ruddle C J, Zinman E J. Thermal injury through intraradicular heat transfer using ultrasonic devices: Precautions and practical preventive strategies. *JADA* 2005 **136**: 1286-1293.
- Sundqvist G, Figdor D. Life as an endodontic pathogen: ecological differences between the untreated and root-filled root canals. *Endodontic Topics* 2003; **6**: 3-28.
- Tronstad L, Sunde P T. The evolving new understanding of endodontic infections. *Endodontic Topics* 2003; **6**: 57-77.
- McDonald A, Setchell D. Developing a tooth restorability index. *Dent Update* 2005; **32**: 343-348.
- Pane E, Palamara J, Messer H. Stainless steel bands in endodontics: effects on cuspal flexure and fracture resistance. *Int Endod J* 2002; **35**: 467-471.
- Jensen A L, Abbott P V, Salgado J C. Interim and temporary restoration of teeth during endodontic treatment. *Aust Dent J* 2007; **52** suppl: S83-99.
- Cohen S, Hargreaves K M. *Pathways of the pulp*, 9th ed. Mosby Elsevier, 2006.
- Magne P, So W S, Cascione D. Immediate dentin sealing supports delayed restoration placement. *J Prosthet Dent* 2007; **98**: 166-174.
- Fox K, Gutteridge D L. An *in vitro* study of coronal microleakage in root canal treated teeth restored by the post and core technique. *Int Endod J* 1997; **30**: 361-368.
- Demarchi M G A, Sato E F L. Leakage of interim post and cores used during laboratory fabrication of custom posts. *J Endod* 2002; **28**: 328-329.
- Messer H H, Wilson P R. Preparation for restoration and temporisation. In: *Principles and practice of endodontics*, 2nd ed. pp 260-276. USA: WB Saunders Co., 1995.
- Lieberman R, Judes H, Cohen E, Eli I. Restoration of posterior pulpless teeth: amalgam overlay versus cast gold onlay restoration. *J Prosthet Dent* 1987; **57**: 540.
- Starr C B. Amalgam crown restorations for posterior pulpless teeth. *J Prosthet Dent* 1990; **44**: 614.
- Lieberman R, Ben-Amar A, Frayberg E, Abramovitz I, Metzger Z. Effect of repeated vertical loads on microleakage of IRM and calcium sulphate-based temporary fillings. *J Endod* 2001; **27**: 724-729.
- Naoum H J, Chandler N P. Review: Temporisation for endodontics. *Int Endod J* 2002; **35**: 964-978.
- Barthel C R, Strobach A, Briedigkeit H, Göbel U B, Roulet J F. Leakage in roots coronally sealed with different temporary fillings. *J Endod* 1999; **25**: 731-734.
- Tanomaru-Filho M, Spinola S G, Reis J M, Chavez-Andrade G M, Guerreiro-Tanomaru J M. *In vitro* sealing ability of temporary restorative materials used in endodontics. *Gen Dent* 2009; **57**: 622-625.
- Seiler K B. An evaluation of glass ionomer-based restorative materials as temporary restorations in endodontics. *Gen Dent* 2006; **54**: 33-36.
- Tapsir Z, Ahmed H M A, Luddin N, Husein A. Sealing ability of various restorative materials as coronal barriers between endodontic appointments. *J Contemp Dent Pract* 2013; **14**: 47-50.
- Lim K C. The microleakage of a glass ionomer cement using two methods of moisture protection. *Quintessence Int* 1987; **18**: 835-839.
- Lim K C. Microleakage of intermediate restorative materials. *J Endod* 1990; **16**: 116-118.
- Nikaido T, Takano Y, Sasafuchi Y, Burrow M F, Tagami J. Bond strengths to endodontically-treated teeth. *Am J Dent* 1999; **12**: 177-180.
- Ari H, Yasar E, Belli S. Effects of NaOCl on bond strengths of resin cements to root canal dentin. *J Endod* 2003; **29**: 248-251.
- Pai S F, Yang S F, Sue W L, Chueh L H, Rivera E M. Microleakage between endodontic temporary restorative materials placed at different times. *J Endod* 1999; **25**: 453-456.
- Stean H. PTFE tape: a versatile material in restorative dentistry. *Dent Update* 1993; **20**: 146-148.
- Khayat A, Lee S J, Torabinejad M. Human saliva penetration of coronally unsealed obturated root canals. *J Endod* 1993; **19**: 458-461.
- Chugal N M, Clive J M, Spångberg L S W. Endodontic treatment outcome: effect of the permanent restoration. *Oral Surg Oral Med Oral Pathol Oral Radiol Endod* 2007; **104**: 576-582.
- Mannocci F, Qualtrough A J, Worthington H V, Watson T F, Pitt Ford T R. Randomized clinical comparison of endodontically treated teeth restored with amalgam or with fibre posts and resin composite: five-year results. *Oper Dent* 2005; **30**: 9-15.
- Mannocci F, Bertelli E, Sherriff M, Watson T F, Ford T R. Three-year clinical comparison of survival of endodontically treated teeth restored with either full cast coverage or with direct composite restoration. *J Prosthet Dent* 2002; **88**: 297-301.
- Fedorowicz Z, Carter B, de Souza R F, de Andrade Lima Chaves C, Nasser M, Sequeira-Byron P. Single crowns versus conventional fillings for the restoration of root filled teeth. *Cochrane Database Syst Rev* 2012; CD009109.
- Hommez G M, Coppens C R, De Moor R J. Periapical health related to the quality of coronal restorations and root fillings. *Int Endod J* 2002; **35**: 680-689.
- Boucher Y, Matossian L, Riillard F, Machtou P. Radiographic evaluation of the prevalence and technical quality of root canal treatment in a French

- subpopulation. *Int Endod J* 2002; **35**: 229–238.
64. Ferrari M, Vichi A, Fadda G M *et al*. A randomized controlled trial of endodontically treated and restored premolars. *J Dent Res* 2012; **91**: S72.
 65. Bolla M, Muller-Bolla M, Borg C, Lupi-Pegurier L, Laplanche O, Leforestier E. Root canal posts for the restoration of root filled teeth. *Cochrane Database Syst Rev* 2007; CD004623.
 66. Capurro M A, Herrera C L, Macchi R L. Influence of endodontic materials on the bonding of glass ionomer cement to dentin. *Endod Dent Traumatol* 1993; **9**: 75–76.
 67. Schwartz R S, Robbins J W. Post placement and restoration of endodontically treated teeth: a literature review. *J Endod* 2004; **30**: 289–301.
 68. Haemmings K W, King P A, Setchell D J. Resistance to torsional forces of various post and core designs. *J Prosthet Dent* 1991; **66**: 325–329.
 69. Sorensen J A, Engleman M J. Ferrule design and fracture resistance of endodontically treated teeth. *J Prosthet Dent* 1990; **63**: 529–536.
 70. Goodacre C J. Designing too preparations for optimal success. *Dent Clin North Am* 2004; **48**: 359–385.
 71. Ilie N, Hickel R. Resin composite restorative materials. *Aust Dent J* 2011; **56** Suppl: 59–66.
 72. Sagsen B, Aslan B. Effect of bonded restorations on the fracture resistance of root filled teeth. *Int Endod J* 2006; **39**: 900–904.
 73. Monga P, Sharma V, Kumar S. Comparison of fracture resistance of endodontically treated teeth using different coronal restorative materials: an *in vitro* study. *J Conserv Dent* 2009; **12**: 154–159.
 74. Xie K X, Wang X Y, Gao X J, Yuan C Y, Li J X, Chu C H. Fracture resistance of root filled premolar teeth restored with direct composite resin with or without cusp coverage. *Int Endod J* 2012; **45**: 524–529.
 75. Smales R J, Hawthorn W S. Long-term survival of extensive amalgams and posterior crowns. *J Dent* 1997; **25**: 225–227.
 76. Plasmans P J, Creugers N H, Mulder J. Long-term survival of extensive amalgam restorations. *J Dent Res* 1998; **77**: 453–460.
 77. Martin J A, Bader J D. Five-year treatment outcomes for teeth with large amalgams and crowns. *Oper Dent* 1997; **22**: 72–78.
 78. Stavropoulou A F, Koidis P T. A systematic review of single crowns on endodontically treated teeth. *J Dent* 2007; **35**: 761–767.
 79. Panitvisai P, Messer H H. Cuspal deflection in molars in relation to endodontic and restorative procedures. *J Endod* 1995; **21**: 57–61.
 80. Aquilino S A, Caplan D J. Relationship between crown placement and the survival of endodontically treated teeth. *J Prosthet Dent* 2002; **87**: 256–263.
 81. Cheung G S P, Chan T K. Long-term survival of primary root canal treatment carried out in a dental teaching hospital. *Int Endod J* 2003; **36**: 117–128.
 82. Salehrabi R, Rotstein I. Endodontic treatment outcomes in a large patient population in the USA: an epidemiological study. *J Endod* 2004; **30**: 846–850.
 83. Tickle M, Milsom K, Qualtrough A, Blinkhorn F, Aggarwal V R. The failure rate of NHS funded molar endodontic treatment delivered in general dental practice. *Br Dent J* 2008; **204**: E8.
 84. Chana H, Kelleher M, Briggs P, Hooper R. Clinical evaluation of resin-bonded gold alloy veneers. *J Prosthet Dent* 2000; **83**: 294–300.
 85. Chrepa V, Konstantinidis I, Kotsakis G A, Mitsias M E. The survival of indirect composite resin onlays for the restoration of root filled teeth: a retrospective medium-term study. *Int Endod J* 2014; **47**: 967–973.
 86. Ozyoney G, Yanikoglu F, Tagtekin D, Hayran O. The efficacy of glass-ceramic onlays in the restoration of morphologically compromised and endodontically treated molars. *Int J Prosthodont* 2013; **26**: 230–234.
 87. Schulte A G, Vockler A, Reinhardt R. Longevity of ceramic inlays and onlays luted with a solely light-curing composite resin. *J Dent* 2005; **33**: 433–442.
 88. Salameh Z, Ounsi H F, Abousheib M N, Al-Hamdan R, Sadiq W, Ferrari M. Effect of different onlay systems on fracture resistance and failure pattern of endodontically treated mandibular molars restored with and without glass fibre posts. *Am J Dent* 2010; **23**: 81–86.
 89. Sorensen J A, Martinoff J T. Endodontically treated teeth as abutments. *J Prosthet Dent* 1985; **3**: 631–636.
 90. Ray H A, Trope M. Periapical status of endodontically treated teeth in relation to the technical quality of the root filling and the coronal restoration. *Int Endod J* 1995; **28**: 12–18.
 91. Tronstad L, Asbjørnsen K, Døving L, Paedersen I, Eriksen H M. Influence of coronal restorations on the periapical health of endodontically treated teeth. *Endod Dent Traumatol* 2000; **16**: 218–221.
 92. Kirkevang L, Ørstavik D, Horsted-Bindslev P, Wenzel A. Periapical status and quality of root fillings and coronal restorations in a Danish population. *Int Endod J* 2000; **33**: 509–515.
 93. Segura-Egea J J, Jimenez-Pinzon A, Poyato-Ferrera M, Velasco-Ortega E, Rios-Santos J V. Periapical status and quality of root fillings and coronal restorations in an adult Spanish population. *Int Endod J* 2004; **37**: 525–530.
 94. Tavares P B L, Bonte E, Boukpepsi T, Siqueira J F, Lasfargues J. Prevalence of apical periodontitis in root canal-treated teeth from an urban French population: influence of the quality of root canal fillings and coronal restorations. *J Endod* 2009; **35**: 810–813.
 95. Bergenholtz G, Nyman S. Endodontic complications following periodontal and prosthetic treatment of patients with advanced periodontal disease. *J Periodontol* 1984; **55**: 63–68.
 96. Karlsson S. A clinical evaluation of fixed bridges, 10 years following insertion. *J Oral Rehabil* 1986; **13**: 423–432.
 97. Jackson C R, Skidmore A E, Rice R T. Pulpal evaluation of teeth restored with fixed prostheses. *J Prosthet Dent* 1992; **67**: 323–325.
 98. Valderhaug J, Jokstad A, Ambjørnsen E, Norheim P W. Assessment of the periapical and clinical status of crowned teeth over 25 years. *J Dent* 1997; **25**: 97–105.
 99. Saunders, W P, Saunders E M. Prevalence of periradicular periodontitis associated with crowned teeth in an adult Scottish subpopulation. *Br Dent J* 1998; **185**: 137–140.
 100. Cheung G S P, Lai S C N, Ng R P Y. Fate of vital pulps beneath a metal-ceramic crown or a bridge retainer. *Int Endod J* 2005; **38**: 521–530.
 101. Weine F S, Wax A H, Wenckus C S. Retrospective study of tapered, smooth post systems in place for 10 years or more. *J Endod* 1991; **17**: 293–297.
 102. Mentink A G, Meeuwissen R, Käyser A F, Mulder J. Survival rate and failure characteristics of the all metal post and core restoration. *J Oral Rehabil* 1993; **20**: 455–461.
 103. Creugers N H, Mentink A G, Käyser A F. An analysis of durability data on post and core restorations. *J Dent* 1993; **21**: 281–284.
 104. Jung R E, Kalkstein O, Sailer I, Roos M, Hämmerle C H. A comparison of composite post buildups and cast gold postandcore buildups for the restoration of nonvital teeth after 5 to 10 years. *Int J Prosthodont* 2007; **20**: 63–69.
 105. Signore S, Benedicenti V, Kaitsas M, Barone F, Angiero F, Ravera G. Long-term survival of endodontically treated, maxillary anterior teeth restored with either tapered or parallel-sided glass-fibre posts and full-ceramic crown coverage. *J Dent* 2009; **37**: 115–121.
 106. Tidehag P, Lundstrom J, Larsson B, Molin M. A 7-year retrospective study of Composipost root canal posts. *J Dent Res* 2004; **83**(Special Issue A): (Abs 4: 080).
 107. Segerström S, Astbäck J, Ekstrand K D. A retrospective long term study of teeth restored with prefabricated carbon fibre reinforced epoxy resin posts. *Swed Dent J* 2006; **30**: 1–8.
 108. Naumann M, Blankenstein F, Dietrich T. Survival of glass fibre reinforced composite post restorations after 2 years – an observational clinical study. *J Dent* 2005; **33**: 305–312.