

# Assessing restored teeth with pulp and periapical diseases for the presence of cracks, caries and marginal breakdown

PV Abbott\*

## Abstract

**Background:** To determine whether clinical examinations and periapical radiographs provide sufficient information to assess the cause of pulp and periapical diseases, the status of teeth when restored and their further treatment needs. Other aims were to determine whether restorations should be removed prior to commencing endodontic treatment, and whether the type and longevity of restorations were related to the presence of disease.

**Methods:** Information was collected regarding 245 restored teeth from 220 consecutive patients referred for endodontic treatment. Teeth were examined before and after the restorations were removed and the findings were compared.

**Results:** Pre-operative examination revealed 47 (19.2 per cent) teeth had caries, 57 (23.3 per cent) had cracks and 96 (39.2 per cent) had marginal breakdown. After restoration removal, the figures were 211 (86.1 per cent), 147 (60 per cent), and 244 (99.6 per cent) respectively. Almost all teeth (93 per cent) had more than one of these factors and periapical radiographs were unreliable indicators of their presence. There was only a 56.1 per cent chance (with 95 per cent Confidence Interval) of finding caries, cracks or marginal breakdown prior to restoration removal. Composite resins were more often associated with early onset and rapid progression of pulp diseases.

**Conclusions:** All restorations should be removed prior to endodontic treatment in order to remove the common factors that may have caused the pulp and periapical disease, and to assess the tooth's prognosis and future treatment needs.

**Key words:** Endodontics, access, restorations, marginal breakdown.

(Accepted for publication 15 September 2003.)

## INTRODUCTION

Whenever any disease is to be treated, there are several general principles that must be followed. The first, and perhaps the most important, is to identify the

disease and its cause which can usually be achieved with a thorough history, clinical examination and appropriate diagnostic tests. Identification of the cause is essential since it must be removed as an integral part of the treatment of the disease. Then the other general principles of treatment can be followed and these include removing the effect of the disease, restoring the tissues to their normal function, monitoring the healing and stability over time, and preventing recurrence of the disease.

It is widely accepted that the most common cause of pulp and periapical diseases is the presence of bacteria within the involved tooth,<sup>1,2</sup> and the most common pathways of entry for these bacteria are via caries, cracks, fractures and open restoration margins. Other possible pathways for bacterial penetration are associated with periodontal disease and dental trauma. Recognition of the presence of caries, cracks, fractures and open restoration margins in any tooth is usually based on visual clinical and radiographic examinations. However, it is very difficult to accurately assess teeth for the presence of these problems when restorations are present since the restoration may 'hide' the problem, and this difficulty increases as the extent of the restoration increases. The presence of a restoration may also hinder the accurate assessment of other important aspects such as the presence and extent of periodontal disease associated with the proximal surfaces of teeth since poorly contoured or broken-down restorations make it difficult to probe these areas.

If a tooth is to be endodontically treated, then its long term prognosis will depend largely on how well it can be restored again after the endodontic treatment has been completed.<sup>3</sup> Some mandatory considerations when assessing the suitability of teeth for further restoration include: is there sufficient tooth structure remaining to enable it to be adequately restored again, is any periodontal treatment required, is crown lengthening surgery required, what type of restoration will be required, are there any alternative restorations that could be used, is a post required for retention of the restoration, how predictable is the treatment (i.e., the endodontic, periodontal and restorative procedures

\*Professor of Clinical Dentistry, University of Western Australia; Endodontist, Private Practice.

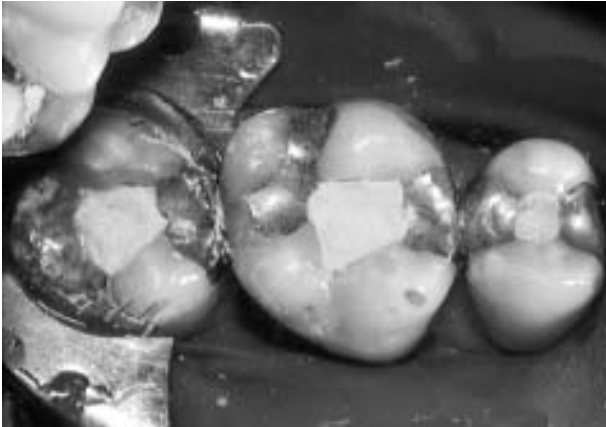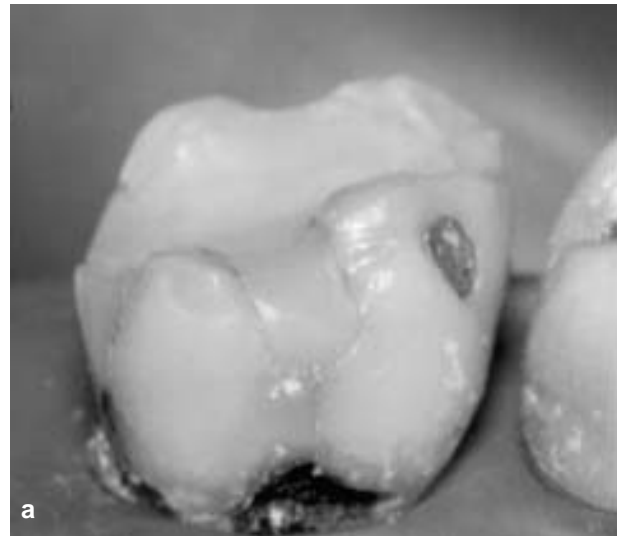


Fig 1. Three teeth with traditional access cavities cut through the existing amalgam restorations.

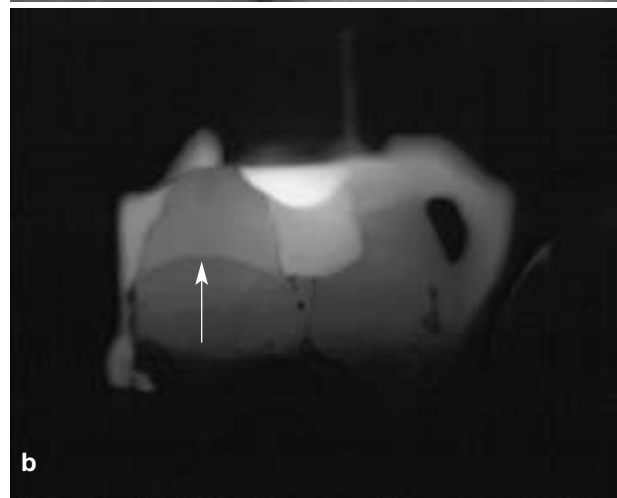combined), or should the tooth be extracted? In some cases, it may even be a question of whether endodontic treatment is required since not all pulp diseases need to be treated in this manner – e.g., reversible pulpitis can usually be managed with simple restorative procedures after removing the irritant that is causing the pulp inflammation.

Most dental practitioners gain access to a root canal system by cutting an access cavity through existing restorations (see Fig 1 for an example) and hence they are unable to consider the above important aspects until after the root canal treatment has been completed and the tooth is being restored again. This is most likely to be a reflection of the traditional teaching of endodontics particularly with respect to access cavities. Most of the commonly-used endodontic textbooks<sup>4-6</sup> do not recommend removal of existing restorations from pulpally-involved teeth and instead they concentrate on outlining the shape, size and position of ‘ideal’ endodontic access cavities for each tooth type. These cavities are usually illustrated on photographs or diagrams of intact teeth, rather than showing the more typical situations encountered clinically where the teeth have various, and often extensive, restorations. One textbook<sup>7</sup> states that it is ‘preferable to remove restorations ... but this is often neither feasible nor desirable’. Unfortunately, the authors of this book do not provide any reasons to support this statement. Another textbook<sup>8</sup> has listed ‘compelling reasons’ and ‘reasons of convenience’ for the removal of restorations in some cases but it did not encourage removing them routinely.

The aims of this study were threefold: firstly to determine whether a standard visual clinical examination and periapical radiographs of teeth and their existing restorations provide sufficient information to accurately assess the status of the teeth and their endodontic treatment needs; secondly to determine whether it is necessary to remove all existing restorations from teeth prior to commencing endodontic treatment in order to remove the cause of the pulp and periapical diseases; and thirdly to



a



b

Fig 2(a). An *in vitro* model showing a lower molar tooth viewed under normal lighting conditions.

(b). The same tooth when transilluminated through the occlusal surface by a fibre optic light. A crack (arrowed) undermining the distal cusp is now readily visible. Restoration margins are also more clearly identifiable.

determine whether the type of restoration and its longevity were related to the presence and progression of the pulp and periapical diseases.

## MATERIALS AND METHODS

Information was collected about a series of 245 teeth in 220 consecutive patients that had been referred to the author for specialist endodontic assessment and treatment. In order to be included in the study, the teeth had to have a restoration in place, some form of pulp and/or periapical pathosis, and no endodontic treatment commenced for that particular disease prior to referral. Teeth with previous root canal fillings were only included if the root filling had been present for more than five years in order to eliminate the possibility of the infection within the canal being a residual infection that had not been removed during the previous treatment. Any teeth with a history of direct trauma or concurrent periodontal disease were

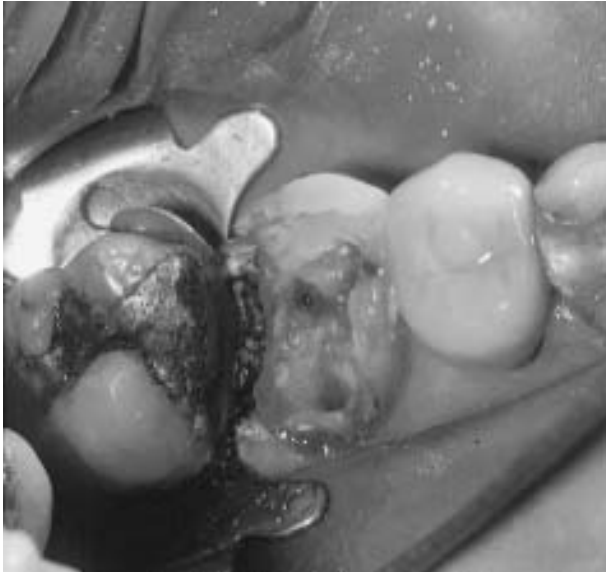

Fig 3. Isolation of an upper first molar tooth using the rubber dam 'cuff technique'.

excluded in order to eliminate these factors as potential causes of the pulp and periapical diseases.

A thorough medical and dental history was recorded for each patient, particularly regarding the tooth or teeth to be treated. The patients were then examined clinically and periapical radiographs were taken of the affected teeth. This information was used to establish a diagnosis of the pulp or root canal condition, and the periapical status. Details were recorded about the restorative material used and the age of the restoration (where known). In some cases, previous dentists were contacted to establish the age of the restoration. Particular attention was placed on examining the teeth for the presence of caries, cracks, fractures and evidence of marginal breakdown of the restoration. The examination method included a visual inspection with probing of restoration margins, probing of pits, fissures and grooves, periodontal probing, percussion, palpation and transillumination of the teeth with a fibre optic light (Fig 2) shone from numerous different directions. Transillumination was performed with extraneous light eliminated from the area by switching off the dental operating light and any other bright lights within the room. Radiographs were examined for the presence of caries and fractures by using ideal viewing conditions with an X-ray viewing light box and a Binoscope (Trollplast, Wollongbar, NSW) to block out peripheral light and to magnify the image (x2).

After discussing the diagnosis and its cause with the patients, the nature of the treatment was outlined in order to obtain the patients' informed consent for treatment. Then, all existing restorations were removed from the affected teeth as the first stage of treatment. The removal of the restorations was designated as 'investigation' of the teeth and this was done under rubber dam isolation in all cases, usually with the 'cuff technique' (Fig 3). The teeth were then examined again

**Table 1. Frequency of treatment of different tooth groups (percentages in parentheses)**

Tooth type	Maxillary	Mandibular	Totals
Incisors	23 (9.4)	1 (0.5)	24 (9.8)
Canines	3 (1.2)	3 (1.2)	6 (2.4)
Premolars	35 (14.3)	17 (6.9)	52 (21.2)
Molars	78 (31.8)	85 (34.7)	163 (66.5)
Totals	139 (56.7)	106 (43.3)	245 (100)

after the restorations had been removed, using the same methods outlined for the pre-operative examination. In particular, transillumination with the fibre optic light was performed on both the coronal and radicular parts of the teeth from all possible angulations and at various stages whilst investigating the teeth once the restorations had been removed. The presence of caries, cracks, fractures and evidence of marginal breakdown were recorded. The teeth were also assessed to determine their endodontic treatment needs and their suitability for further restoration following endodontic treatment. The findings were recorded and analyzed by frequency. Odds ratios were calculated in order to determine the chances of being able to detect caries, cracks or marginal breakdown pre-operatively.

The following criteria were used: caries was recorded if there was softening or loss of tooth structure; marginal breakdown was noted if there was staining of the tooth structure extending from the margins of the cavity into dentine; and cracks were recorded if both enamel and dentine were involved but the fragments on either side of the defect could not be separated from each other during probing of the crack line. If the tooth fragments could be separated from each other then the defect was recorded as a fracture. A distinction was drawn between craze lines (infractures) – which only involve enamel – and cracks. Craze lines were not recorded as these are unlikely to be a cause of pulp disease.

## RESULTS

The 220 patients consisted of 155 (70.4 per cent) females and 65 males (29.6 per cent). The females had 168 (68.6 per cent) teeth treated whilst the males had 77 (31.4 per cent) teeth treated. Most patients (199, 90.4 per cent) had just the one tooth treated but 18 (8.2 per cent) had two teeth, two patients (1 per cent) had three teeth, and one patient (0.4 per cent) had four teeth treated. Table 1 lists the frequencies of the various tooth types included in this study.

The restorations were classified according to the type of restorative material used. Five teeth had both amalgam and composite resin restorations present and in all five cases, the composite resin was the restoration associated with caries and marginal breakdown – hence these teeth were included in the composite resin group. Teeth restored with full crowns were classified as crowns and the type of core material used was not considered unless a post had been used. The final

**Table 2. Age of the existing restorations**

Age (years)	Amalgam	Composite	Crowns	Posts/Crowns	Totals
<1	3	14	1	–	18
1	5	15	–	–	30
2	1	30	5	–	36
3	6	11	3	1	21
4	5	2	–	–	7
5	7	2	1	1	11
6-10	14	3	2	4	23
11-15	3	–	2	1	6
16-20	2	–	2	–	4
21-25	2	–	5	2	9
>25	–	–	1	1	2
Patient cannot recall (but >10 yrs)	83	–	5	–	88
Totals	131	77	27	10	245

numbers of each group were: amalgam – 131 teeth (53.5 per cent); composite resin – 77 teeth (31.4 per cent); crowns – 27 teeth (11 per cent); and post-retained crowns – 10 teeth (4.1 per cent). The age of the restorations is summarized in Table 2. Unfortunately, some patients could not recall when the restorations (83 amalgams and five crowns) had been placed and the details could not be obtained from previous dentists. However, all of these patients stated that the restorations had been placed more than 10 years ago.

The status of the pulp or root canal system was classified using a 'clinical classification' based on the presence of inflammation or infection. Infection was noted clinically by the presence of swelling, fever, and lymphadenopathy in acute cases, or radiographically by the presence of a periapical radiolucency indicating an infected root canal system. The findings are listed in Table 3, according to the type of restorative material present. Eighteen teeth (7.4 per cent) were assessed as not requiring endodontic treatment – seven (2.9 per cent) had reversible pulpitis (see Table 3) and 11 (4.5 per cent) were recommended for extraction. The teeth with reversible pulpitis (one incisor, one premolar and five molars) were managed conservatively by placement of a sedative lining and a temporary restoration to allow the pulpitis to resolve. They were then reviewed after three months and tests indicated that the pulpitis had resolved in all seven cases. The 11 teeth (two incisors, two premolars and seven molars) recommended for extraction either had vertical root fractures, cracks extending into the tooth root, or they were not suitable for further restoration due to a lack

of remaining tooth structure. Five teeth with amalgams (3.8 per cent of the amalgam group) were recommended for extraction, three with composite resins (3.9 per cent) and three with full crowns (11.1 per cent) but none of the teeth with posts. The remaining 227 teeth (92.6 per cent) required endodontic treatment.

Periapical radiographs were taken of every tooth prior to treatment and these were assessed for any evidence of caries but this could only be diagnosed in 47 teeth (19.2 per cent). In contrast, caries was clinically found in 211 teeth (86.1 per cent) after the restorations had been removed (Table 4). There was a similar lack of correlation between the clinical findings regarding the presence of marginal breakdown, caries and cracks prior to treatment and the findings noted after the restorations were removed. This applied for all types of restorations with a marked increase in discovery of these problems once the restoration had been removed. About one third of the teeth were identified pre-operatively as having marginal breakdown whereas all but one tooth had evidence of marginal breakdown once the restorations had been removed. Caries was difficult to detect pre-operatively in all teeth, but particularly in teeth with composite resins (noted in only 9.1 per cent pre-operatively, but 87 per cent post-operatively). Teeth with crowns had caries detected in 16.2 per cent pre-operatively compared with 81.1 per cent post-operatively, while 23 per cent of teeth with amalgam were noted pre-operatively with caries compared with 87 per cent post-operatively. Cracks were detected in about one third of teeth with amalgams, but in only 7.8 per cent of those with composites and none in crowned teeth. After restoration removal, the number of cracks noted increased to about two thirds of the amalgam group, just over half of the composite group and about one third of the crown group.

Odds ratio calculations with a 95 per cent Confidence interval indicated that there was only a 56.1 per cent chance of detecting the presence of caries, cracks or leaking restoration margins prior to removing the restorations from teeth with pulp and periapical diseases.

## DISCUSSION

This study was designed to simulate the typical treatment approach adopted by clinicians. The teeth

**Table 3. Diagnosis of the pulp and root canal condition associated with the different restorative materials (percentages in parentheses represent the percent of teeth for each restorative material)**

Diagnosis	Amalgam	Composite	Crowns	Posts/Crowns	Totals
Reversible pulpitis	6 (4.6%)	–	1 (3.7%)	–	7 (2.9%)
Irreversible pulpitis	67 (51.2%)	16 (20.8%)	5 (18.5%)	–	88 (35.9%)
Necrosis and infection	4 (3.0%)	2 (2.6%)	–	–	6 (2.4%)
Pulpless and infected	41 (31.3%)	34 (44.1%)	7 (25.9%)	–	82 (33.5%)
RCF* and infection	13 (9.9%)	25 (32.5%)	14 (51.9%)	10 (100%)	62 (25.3%)
Totals	131 (100%)	77 (100%)	27 (100%)	10 (100%)	245 (100%)

\*RCF=Root canal filling.

**Table 4. Comparison of the clinical and radiographic pre-operative findings with the post-operative findings after the restorations had been removed**

	Amalgam (n=131)		Composite (n=77)		Crowns (n=37)		All teeth (n=245)	
	Pre-op	Post-op	Pre-op	Post-op	Pre-op	Post-op	Pre-op	Post-op
Nil	53 (40.5%)	1 (0.8%)	39 (50.6%)	0	15 (40.5%)	0	107 (43.7%)	1 (0.4%)
Marginal breakdown	41 (31.3%)	130 (99.2%)	33 (42.9%)	77 (100%)	22 (59.5%)	37 (100%)	96 (39.2%)	244 (99.6%)
Caries – radiograph	23 (17.6%)	N/A	14 (18.2%)	N/A	10 (27.0%)	N/A	47 (19.2%)	N/A
Caries – clinical	31 (23.6%)	114 (87.0%)	7 (9.1%)	67 (87.0%)	6 (16.2%)	30 (81.1%)	44 (18.0%)	211 (86.1%)
Cracks	51 (38.9%)	91 (69.5%)	6 (7.8%)	42 (54.6%)	0	14 (37.8%)	57 (23.3%)	147 (60.0%)

Percentages in parentheses apply to each restorative material. (Note: the sum of each row and column is not equal to the sample size as 93% of teeth had more than one causative factor present.)

examined were from consecutive patients in order to remove any bias in case selection. The only teeth excluded from the study were those with factors or histories that indicated potential causes of the pulp and periapical diseases other than caries, cracks, fractures or breakdown of restoration margins. Examinations and clinical procedures were all performed by the one operator in order to exclude individual variations between different operators and to further simulate the typical clinical scenario.

Overall, 107 teeth (43.7 per cent) were judged to be free of signs of marginal breakdown, caries, cracks and fractures when initially examined but 244 (99.6 per cent) had at least one of these problems and 93 per cent had more than one problem noted after the restorations were removed. Only one tooth (see below) did not have any signs of marginal breakdown, caries or cracks that may have allowed bacteria to enter the tooth system and initiate the pulp and periapical diseases. Hence, the results of this study clearly indicate that the standard visual clinical examination performed by dentists is an unreliable indicator of the presence of marginal breakdown, caries, cracks and fractures in restored teeth with pulp and/or periapical disease. An important implication of this finding is that the cause of these diseases is difficult, and perhaps impossible, to identify in every case with a standard clinical examination. This may then imply that the cause will not be removed if it has not been identified by the clinician which can easily lead to failure of treatment and the development of further symptoms and disease. Many clinicians might expect to see failure soon after the completion of treatment but this is not usually the case with endodontic treatment since the reduction in bacterial count within the root canal, or the removal of inflamed pulp tissue, is usually enough to remove the symptoms in the short term. The time taken for symptoms to develop when an acute exacerbation of chronic apical periodontitis occurs after bacteria have entered a tooth is typically 1-5 years. Patients presenting with symptoms such a short time after endodontic treatment is unfortunately a very common occurrence as demonstrated by two large studies<sup>9,10</sup> of root-filled teeth requiring further treatment due to failure of the initial endodontic treatment. In the first of these studies which involved 1300 teeth, Allen *et al.*<sup>9</sup> reported that 21.9 per cent presented less than one year after treatment, 37.3

per cent between 1-2 years and 13.7 per cent between 2-5 years for a cumulative total of 72.9 per cent within five years. In the other study, Abbott<sup>10</sup> reported 21.2 per cent of 575 failures presented after less than one year, 15.8 per cent between 1-2 years and 24 per cent between 3-5 years for a cumulative total of 61 per cent within five years. Although not investigated in these studies, it is feasible that one possible reason for the early failure of treatment was the lack of removal of the cause of the original disease by not removing the broken down restoration, the caries or the cracks since traditional endodontic teaching has not recommended this. The typical teaching of endodontics, and therefore the typical treatment approach taken by dentists, has been to access the root canal system by cutting an 'ideal' access cavity through the tooth and through any existing restorations – such 'ideal' access cavities are described and illustrated in endodontic textbooks. The results of this study clearly indicate that this approach needs to be modified and all existing restorations should be removed as the very first stage of endodontic treatment in order to remove the cause of the disease and to allow adequate assessment of the tooth prior to committing the patient to having extensive treatment.

Only one tooth did not have evidence of caries, cracks or marginal breakdown when the patients presented with pulp and/or periapical disease. This particular tooth had been restored just eight months prior to referral because the previous restoration had fractured as a result of caries. A periapical radiograph (Fig 4) showed a medium-sized periapical radiolucency and partially obliterated root canals. This radiograph, together with the history, clinical examination and pulp sensibility tests indicated that the lower right first molar had a pulpless, infected root canal system and chronic apical periodontitis. The size of the radiolucency (5-6mm diameter) suggests that it was very likely to have been present when the restoration was replaced. Hence, when the details of this case are considered, it is not unreasonable to state that all teeth in this study had caries, cracks, fractures or marginal breakdown of restorations (or combinations of these) that had contributed to the development of, or had caused the pulp and periapical diseases.

Periapical radiographs were unreliable indicators of the presence of caries in restored teeth with pulp and/or

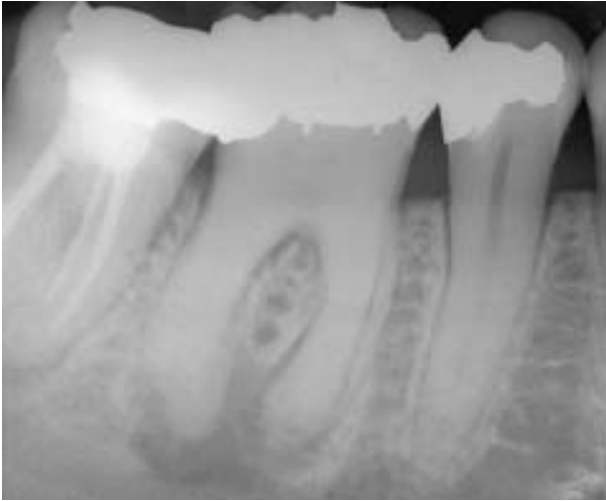

Fig. 4 Tooth 46 – Periapical radiograph of the only tooth in the study that did not have caries, cracks or marginal breakdown evident when the existing restoration was removed. However, the restoration had been replaced only eight months prior to being examined as part of the current study.

periapical disease, even when they were examined under ideal viewing conditions. Caries was noted from the radiographs in only 47 (19.2 per cent) teeth but examination after restoration removal showed that 211 (86.1 per cent) teeth actually had caries. Bitewing radiographs may have been of more value in detecting caries but they are not routinely recommended or taken by endodontists as part of an endodontic examination except where there is any doubt about the diagnosis prior to initiating treatment. The results of this study suggest that bitewing films may need to be taken more often when assessing pulp and periapical diseases. The other factors examined in this study (marginal breakdown and cracks) can not be detected radiographically and hence they were not assessed in this part of the study.

Cracks and fractures can be difficult to visualize when restorations are present. When all teeth in this study were considered, 57 (23.3 per cent) were diagnosed pre-operatively as having cracks but 147 (60 per cent) were found to have cracks after the restorations were removed. Teeth with crowns did not have any cracks or fractures detected on initial examination but 14 (37.8 per cent) were found to have cracks after restoration removal. Cracks were more difficult to detect in teeth with composite resins since only six (7.8 per cent) were diagnosed pre-operatively and 42 (54.6 per cent) were found later. Cracks in teeth with amalgam restorations were easier to detect pre-operatively but there was still a notable increase in the number detected once the restorations had been removed - 51 (39 per cent) pre-operatively compared with 91 (69 per cent) after restoration removal. Most cracks were detected when the teeth were transilluminated with a fibre optic light which is a very simple, cheap and effective method of revealing cracks and fractures. However, despite the ease of use and the

great diagnostic value of this technique, the concept of shining a narrow beam of strong light through teeth is not commonly utilized by dentists. The principle of transillumination of teeth works because the light beam is deflected once it reaches a crack or fracture which then appears as a dark line (Fig 2). Only the side of the tooth from which the light is being shone will be illuminated by the light and the contralateral side of the crack or fracture will remain dark. This procedure relies on contrast and therefore all extraneous light must be eliminated from the area which can be easily achieved by turning off the dental operating light and any other bright lights within the room.

The most common pulp disease associated with each restoration varied and when this is considered with the age of the restoration, there are some very interesting findings (Table 2-3). The most common pulp condition associated with amalgam restorations was irreversible pulpitis (50.4 per cent), whilst 72.7 per cent of the composite resins had infected canals (either pulpless and infected - 40.2 per cent; or previously root-filled and infected - 32.5 per cent). The amalgam restorations had generally been present for a long time when the patients presented with the pulp disease (68.7 per cent over 10 years, and 10.7 per cent between 6-10 years). In contrast, 91 per cent of the composite resins had pulp and periapical disease within three years and the remainder by seven years. Hence, the 'typical amalgam' restoration in this study lasted a long time before symptoms of pulpitis developed, which indicates marginal breakdown many years after the restoration was placed. In contrast, teeth with a 'typical composite' restoration had passed through all of the progressive stages of pulp disease (i.e., reversible pulpitis, irreversible pulpitis, necrosis, canal infection, pulpless<sup>11</sup>) and then developed apical periodontitis within just three years. This indicates that they probably had marginal breakdown soon after the restoration had been placed since this pulp disease cycle typically takes between 1-5 years.

In this study, seven (2.9 per cent) teeth did not require endodontic treatment as the pulpitis was reversible. The provisional diagnosis of reversible pulpitis was subsequently confirmed in all seven cases when the teeth were re-examined three months after removing the irritants and placing temporary restorations with sedative linings. These teeth demonstrate the importance of an accurate diagnosis and the need to 'investigate' teeth by removing restorations before finalizing a treatment plan. This approach avoided 'over-treatment' of these teeth which would have occurred if root canal therapy had been performed, as requested by the referring dentists.

Eleven teeth (4.5 per cent) were recommended for extraction because they had extensive loss of tooth structure, vertical root fractures, or cracks extending into the root - all of which rendered them unsuitable for further restoration. Removal of the restorations meant that these problems were discovered prior to the

commencement of endodontic treatment. If these problems had not been identified prior to endodontic treatment being commenced, these patients would have had on-going symptoms or a recurrence of symptoms at a later date. These teeth would have been considered as having had endodontic treatment failures even though the 'failure' would have been a failure to adequately diagnose, assess and manage the original problem and its cause.

Odds ratio calculations show that there is only a 56.1 per cent chance of finding caries, cracks and marginal breakdown in 95 per cent of restored teeth that have pulp and/or periapical disease. Hence, the results of this study clearly indicate that it is essential to remove all existing restorations from teeth with pulp and/or periapical disease prior to commencing endodontic treatment. This allows the caries, cracks and faulty restorations to be removed which implies that the most likely cause(s) of the disease will be removed, in addition to preventing bacterial penetration during treatment, allowing assessment of the tooth's suitability for further restoration, and helping to assess whether endodontic treatment is required. Removing the restorations also allows the clinician to assess how the tooth can be restored again, whether any other treatment is required and what the overall prognosis is likely to be. This study also clearly demonstrates that endodontic access cavities should not be made through existing restorations except in occasional cases where a recent restoration has been placed and the pulpitis has developed as a result of the operative procedure. In such a case, caution is required and a full re-evaluation of the restoration would be indicated. However, the results also suggest that it would be difficult to justify leaving any composite resin restorations in place as they may be associated with pulp demise in some teeth even within a very short period of time after being placed.

## CONCLUSIONS

Clinical examination and periapical radiographs do not provide sufficient information to enable clinicians to accurately assess teeth that have been previously restored and have pulp and/or periapical pathosis. The presence of the most common causes of pulp and periapical disease (marginal breakdown, caries, cracks and fractures) can not be fully diagnosed without removing the existing restoration. These causative factors must be recognized, and removed, before commencing endodontic treatment.

## ACKNOWLEDGEMENT

The author wishes to acknowledge the advice and assistance with the statistical analysis that was generally provided by Mr Peter Kahn.

## REFERENCES

1. Kakehashi GH, Stanley HR, Fitzgerald RL. The effects of surgical exposure of dental pulps in germ-free and conventional laboratory rats. *Oral Surg Oral Med Oral Pathol* 1965;20:340-349.
2. Sundqvist G. Bacteriologic studies of necrotic dental pulps. Umea: University of Umea, 1976. DODont thesis.
3. Saunders WP. Restoration of the root filled tooth. In: Orstavik D, Pitt Ford TR, eds. *Essential endodontology. Prevention and treatment of apical periodontitis*. Oxford: Blackwell Science, 1998;3313-66.
4. Burns RC, Herbranson EJ. Tooth morphology and cavity preparation. In: Cohen S, Burns RC, eds. *Pathways of the Pulp*. 7th edn. St Louis: CV Mosby, 1998:150-202.
5. Ingle JI, Mullaney TA, Grandich RA, Taintor JF, Fahid A. Endodontic cavity preparation. In: Ingle JI, Taintor JF, eds. *Endodontics*. 3rd edn. Philadelphia: Lea & Febiger, 1985:102-225.
6. Weine FS. Access cavity preparation and initiating treatment. In: Weine FS, ed. *Endodontic therapy*. 4th edn. St Louis: CV Mosby, 1989:219-276.
7. Walton RE. Access preparation and length determination. In: Walton RE, Torabinejad M, eds. *Principles and practice of endodontics*. 2nd edn. Philadelphia: WB Saunders Co, 1996:180-200.
8. Gutmann JL, Lovdahl PE. Problems encountered in tooth isolation and access to the pulp chamber space. In: Gutmann JL, Dumsha TC, Lovdahl PE, Hovland EJ, eds. *Problem solving in endodontics. Prevention, identification and management*. 3rd edn. St Louis: Mosby-Year Book Inc, 1997:47-68.
9. Allen RK, Newton CW, Brown CE. A statistical analysis of surgical and nonsurgical endodontic retreatment cases. *J Endod* 1989;15:261-266.
10. Abbott PV. A retrospective analysis of the reasons for, and the outcome of, conservative endodontic re-treatment and periradicular surgery. *Aust Dent J* 1999;44:S3-S4.
11. Abbott PV. The periapical space – a dynamic interface. *Ann R Australas Coll Dent Surg* 2000;15:223-234.

*Address for correspondence/reprints:*

Professor Paul V Abbott  
School of Dentistry  
The University of Western Australia  
Oral Health Centre of WA  
17 Monash Avenue  
Nedlands, Western Australia 6009  
E-mail: pvabbott@cyllene.uwa.edu.au