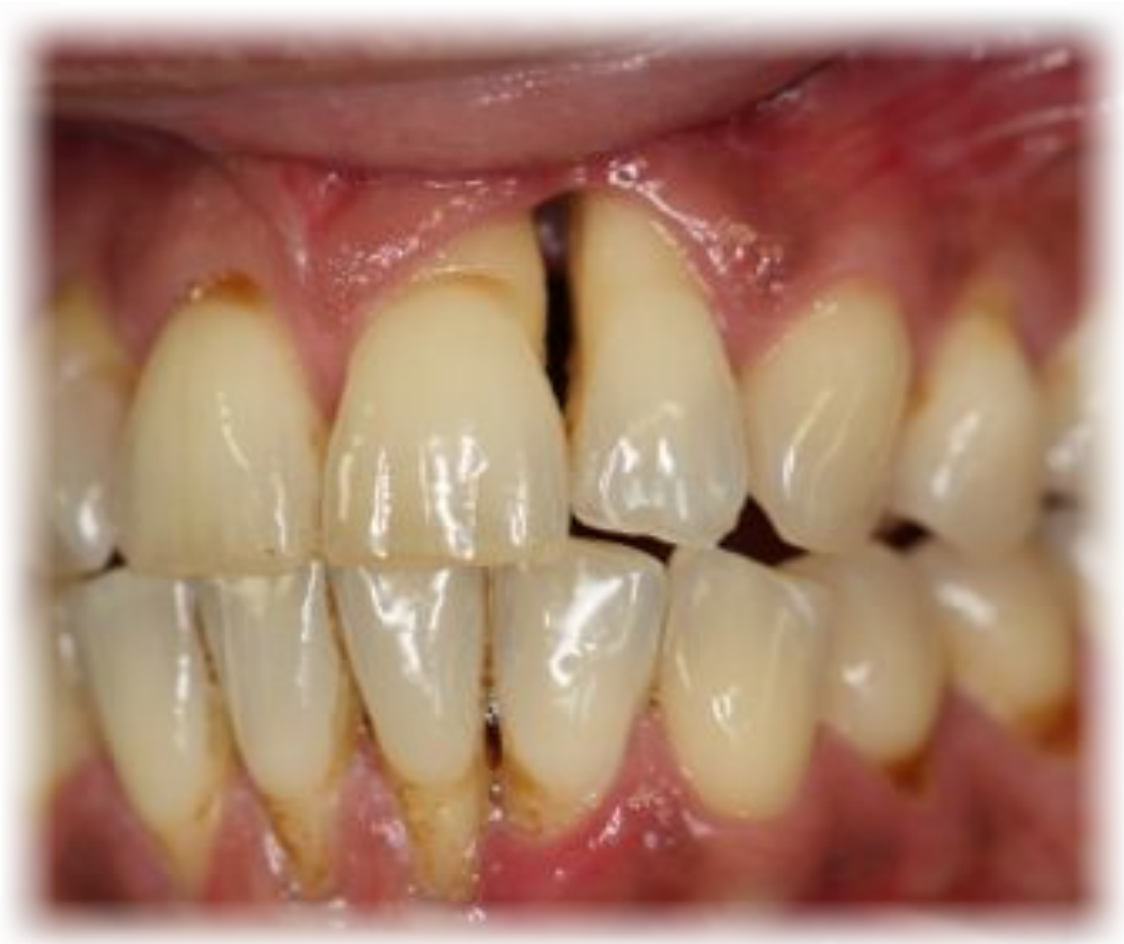
UL12

Periodontal Destruction
July 2012

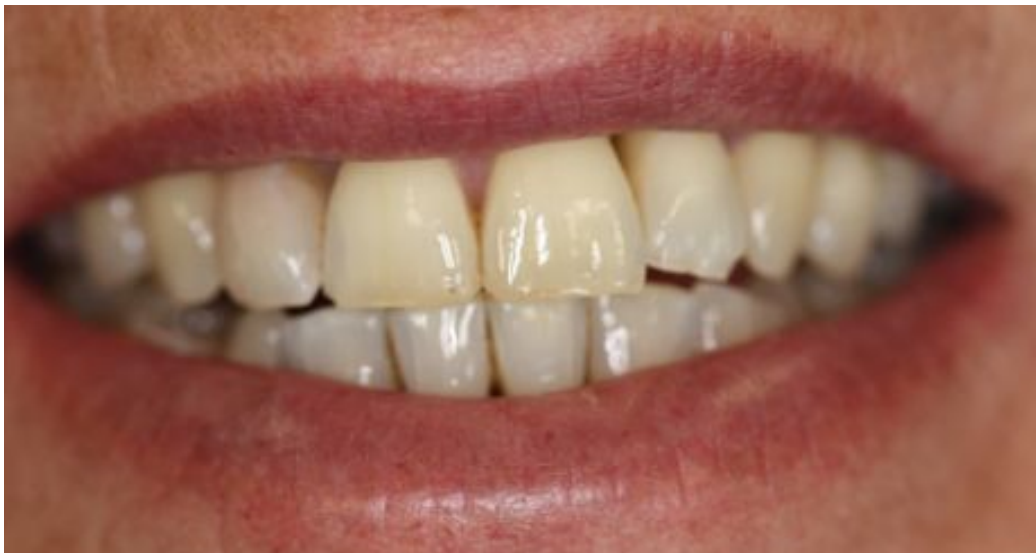

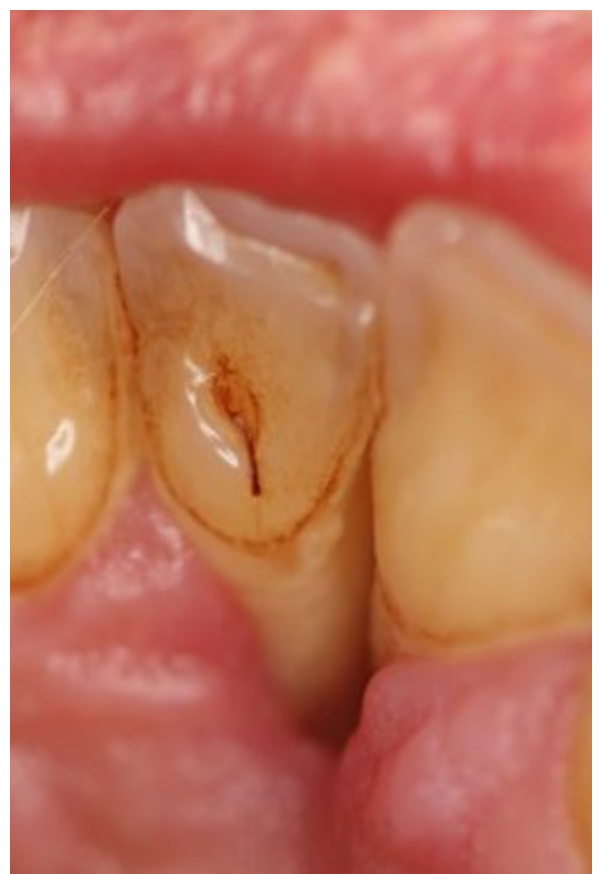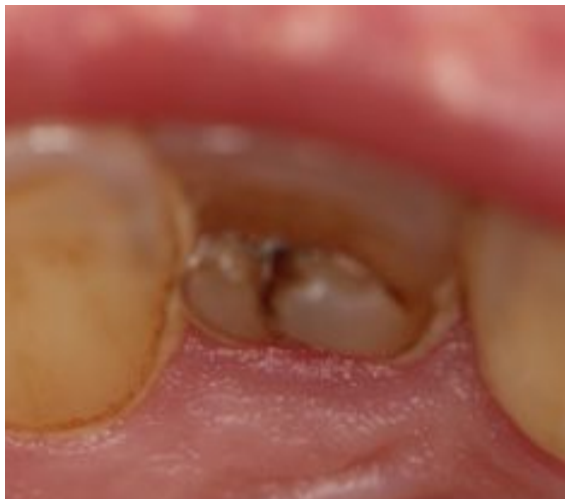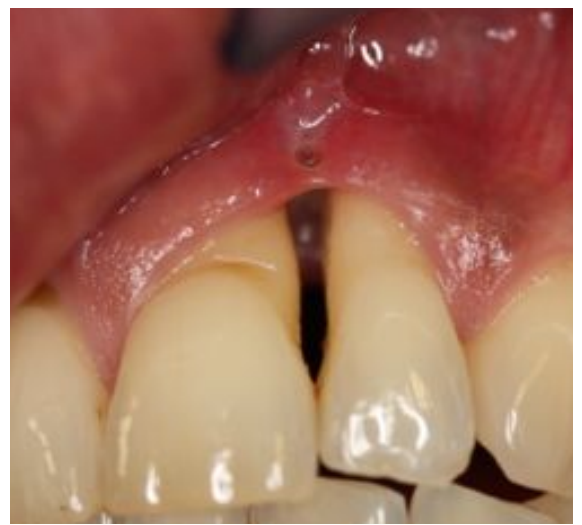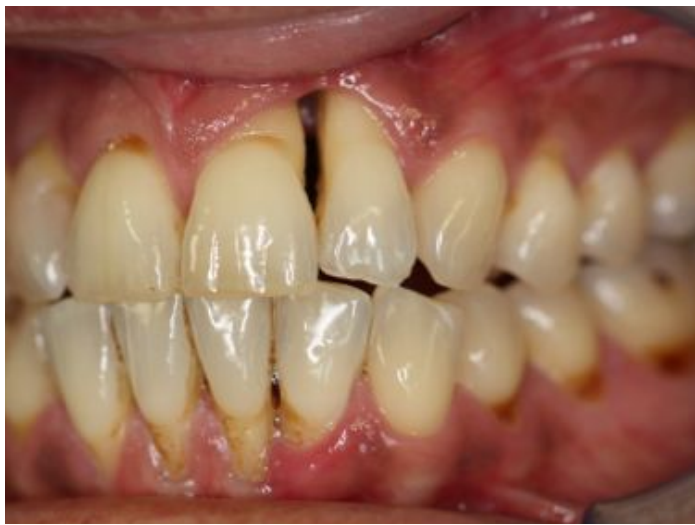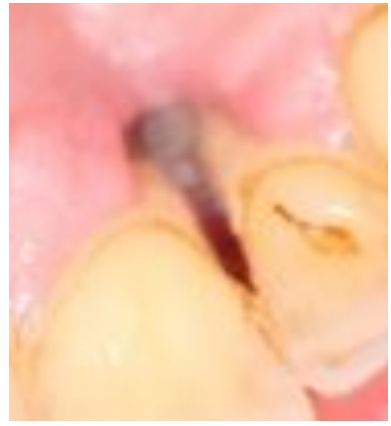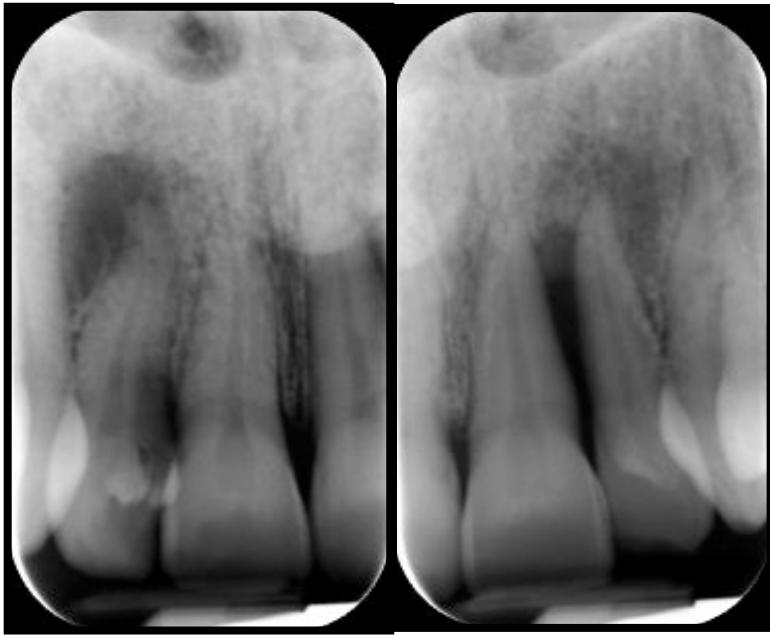
A 48 yr old female patient presents with concerns regarding the upper left central and lateral incisor regions.

She has noticed 'gum shrinkage' happening over the last 6 months. She is concerned about the appearance and terrified of losing her teeth. She has mild thermal sensitivity in this area but this is not significantly worse compared with other areas in her mouth.

She has a history of psychiatric illness (schizophrenia - Aripiprazole) but is physically well. She smokes 40 cigarettes per day and has done since she was a teenager. She is unemployed and quite timid. She has no children but is in a long term relationship with a man.

She has visited her current dentist regularly over the last three years but was an erratic attender prior to this. She likes her current dentist as she feels they are the first to show no prejudice regarding her mental illness. She is very pleasant and keen for help. She openly admits she doesn't feel she can stop smoking.





Questions:

1. What are the differential diagnosis?
2. What, if any, further investigations would you prescribe?
3. Discuss the treatment options?
4. Is this likely to occur elsewhere?
5. What bacterial species/ pathology may be involved?
6. Could this be viral or fungal?
7. Would a regenerative procedure be possible?
8. Could this disease be classified?